

Morphological features of the distal ileum and ceca of the common pigeon (*Columba livia*)

Anietie Francis Udoumoh, Udensi Maduabuchi Igwebuike, Wilfred Ikechukwu Ugwuoke

Department of Veterinary Anatomy, Faculty of Veterinary Medicine, University of Nigeria, Nsukka 410001, Enugu State, Nigeria

Abstract

Background to the study: Common pigeon (*Columba livia*) is widely distributed worldwide and feeds mainly on grains or seeds and insects and small invertebrates. Some studies have demonstrated variations in the morphology and function of avian alimentary tract. **Methods:** Ten apparently healthy adult common pigeons were examined in this study. Following euthanasia, gross and histological techniques were used to investigate the morphology of the distal ileum and ceca of common pigeon. **Results:** At the ileo-ceco-rectal junction, the tunica muscularis of the distal ileum exhibited a thickened layer of oblique smooth muscle fibers positioned between the middle circular and outer longitudinal smooth muscle layers. The ceca of the common pigeon were paired, small (approximately 0.33 cm), blind-ended sacs situated at acute angles with the distal ileum. Histologically, each cecum exhibited a lamina propria-submucosa that contained aggregates of lymphocytes and few glandular acini throughout the length of the organ. **Conclusion:** It was suggested that the ceca of the common pigeon may be important in immunological response of the bird to invasion by antigens while playing some roles in the digestion of food materials. Moreover, the thickened oblique layer of smooth muscle fibers in the wall of the distal ileum may serve to regulate the passage of materials through the ileo-ceco-rectal orifice.

Key words: Cecum, common pigeon, distal ileum, lamina propria-submucosa, sphincter

INTRODUCTION

Common pigeon (*Columba livia*) is widely distributed worldwide and feeds mainly on grains or seeds (Cininari *et al.*, 2005) and insects and small invertebrates (Jokimati and Suhonen, 1998). Some studies have demonstrated variations in the morphology and function of avian

alimentary tract, and these may be related to evolutionary events, type and nature of food intake, and habitat (Parchami and Dehkordi, 2011). Components of the avian digestive tract include two blind-ended sacs, the ceca, which are highly variable in size, but are usually more conspicuous in plant-eating birds. The ceca are considered sites for microbial fermentation of plant materials and are thought to also play significant roles in the defense of the body against invasion by antigens (Klasing, 1998; Igwebuike and Eze, 2010). Many studies have reported on the morphology of the avian ceca in chicken (Rezaian

Address for correspondence:

Dr. Anietie Francis Udoumoh,
Department of Veterinary Anatomy, Faculty of Veterinary Medicine,
University of Nigeria, Nsukka 410001, Enugu State, Nigeria.
E-mail: anietie.udoumoh@unn.edu.ng

Access this article online

Quick Response Code:



Website:
www.jecajournal.com

DOI:
10.4103/1596-2393.190827

This is an open access article distributed under the terms of the Creative Commons Attribution-NonCommercial-ShareAlike 3.0 License, which allows others to remix, tweak, and build upon the work non-commercially, as long as the author is credited and the new creations are licensed under the identical terms.

How to cite this article:

Udoumoh, A. F., Igwebuike, U. M., & Ugwuoke, W. I. (2016). Morphological features of the distal ileum and ceca of the common pigeon (*Columba livia*). *Journal of Experimental and Clinical Anatomy*, 15(1), 27-30.

and Hamedi, 2007; Majeed *et al.*, 2009), African pied crow (Igwebuikwe and Eze, 2010), Owl (Mot, 2010), duck (Dziala-Szczepanczyk and Wesolowska, 2008), ostrich (Durities and Mugurevics, 2011), guinea fowl (Kasperska, *et al.*, 2012), and quail (Zaher, *et al.*, 2012); however, the mechanism by which the passage of food materials through the ileo-ceco-rectal orifice is regulated has remained a subject of controversy among researchers (Clarke, 1978; Duke, 1986; Mahdi and McLelland, 1988). Moreover, there is a paucity of information on the morphology of the distal ileum and ceca of the common pigeon. Thus, the present study undertakes to provide information on the histomorphology of the ceca and distal ileum of the common pigeon.

MATERIALS AND METHODS

Animals

Ten adult common pigeons of mean weight 325.4 ± 6.12 g were used for the study. They were obtained from local markets in Nsukka Local Government Area, Enugu State, Nigeria. The birds were humanely sacrificed by euthanasia. This was achieved by intravenous administration of ketamine (0.1 ml/g body weight of bird).

Gross Anatomy

Following death, the intestines were dissected and the shape, physical appearance, and *in-situ* topographical relationships of the distal ileum and ceca were studied. Photographs were captured with a Sony® 14.1-megapixel digital camera.

Histological Preparation

Segments of the ceca and distal part of the ileum were fixed by immersion in Bouin's fluid for 48 h. These were later dehydrated in increasing concentrations of ethanol, cleared in xylene, and embedded in paraffin wax. Following mounting on wooden blocks, 5 µm thick sections were obtained with a rotary microtome. The sections were mounted on glass slides and stained with hematoxylin and eosin for light microscopy. Photomicrographs were captured using a Moticam® digital camera (Motic China Group Co., Ltd, Xiamen, China).

RESULTS

Gross Anatomical Features of the Ceca

The large intestine of the common pigeon (*C. livia*) exhibited two ceca, which appeared as blind-ended sacs that extended from the junction of the coloproctum and the distal part of the ileum. Each cecum was approximately 0.33 cm in length and was situated at an acute angle with the distal part of the ileum. The tips of the ceca were cranially directed [Figure 1].

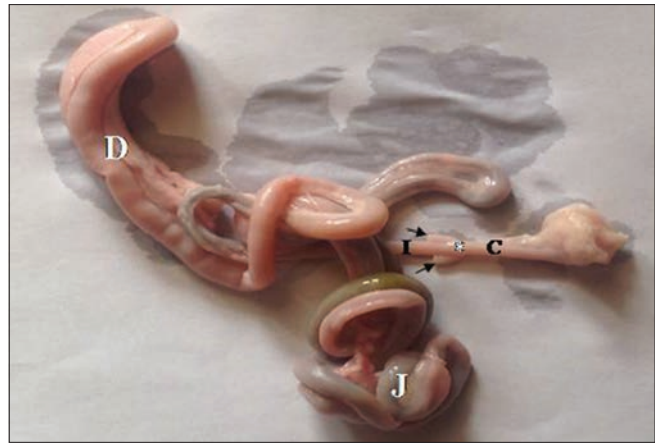


Figure 1: Photograph of the digestive tract of the common pigeon (*Columba livia*) showing the two ceca (arrows). Note the duodenum (D), jejunum (J), ileum (I), ileo-ceco-rectal junction (asterisk) and the coloproctum (C)

Histological Features of the Distal Ileum

The wall of the distal ileum was composed of tunica mucosae, tunica submucosa, tunica muscularis, and tunica serosa. The tunica mucosae were thrown into villous folds which were lined by simple columnar epithelium. The epithelium contained several goblet cells. The submucosa of the distal ileum contained numerous glands while the tunica muscularis exhibited inner longitudinal, middle circular, and outer longitudinal layers of smooth muscle cells. At the ileo-ceco-rectal junction, the tunica muscularis showed a thickened layer of oblique smooth muscle fibers positioned between the middle circular and outer longitudinal smooth muscle layers [Figure 2].

Histological Features of the Ceca

The luminal surface of each cecum was covered by lamina epithelialis mucosae of simple columnar epithelium. Beneath the epithelium, there was a loose connective tissue layer, the lamina propria-mucosae. The lamina muscularis mucosae were lacking in the cecum of the common pigeon, such that the connective tissue of the lamina propria was continuous with the subjacent tunica submucosa, thus forming the lamina propria-submucosa [Figure 3]. This broad connective tissue layer contained many lymphoid aggregations and few glandular acini. A tunica muscularis was present, and the smooth muscles of this tunic were characteristically arranged within three layers namely inner longitudinal, middle circular, and outer longitudinally arranged layers [Figures 4 and 5]. Blood vessels and nerve plexuses were apparent within the tunica muscularis. The tunica serosa was evident as a thin layer of connective tissue lined by a simple squamous epithelium on its external surface [Figures 3-5].

DISCUSSION

Morphological features of avian digestive tract are thought to be generally adapted to the feeding habit, food type,

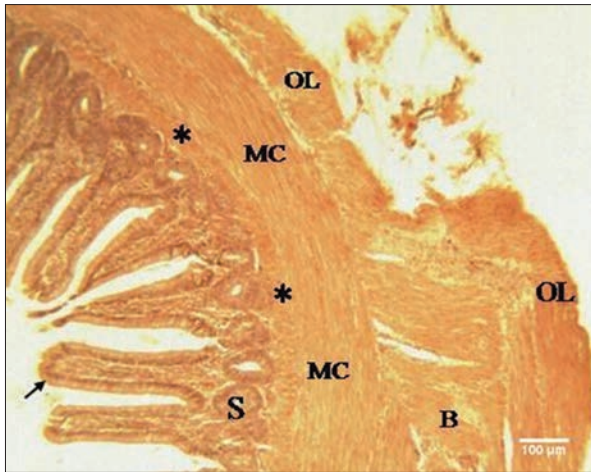


Figure 2: Photomicrograph of the distal ileum at ileo-ceco-rectal junction showing modification of the tunica muscularis into an inner longitudinal (asterisk), middle circular (MC), and outer longitudinal (OL) layers of smooth muscle. Note an oblique smooth muscle layer (B) between the middle circular and outer longitudinal smooth muscle layers; the tunica submucosa (S); and the finger-like villous projections (arrow) (H and E, x100) scale bar = 100 μm

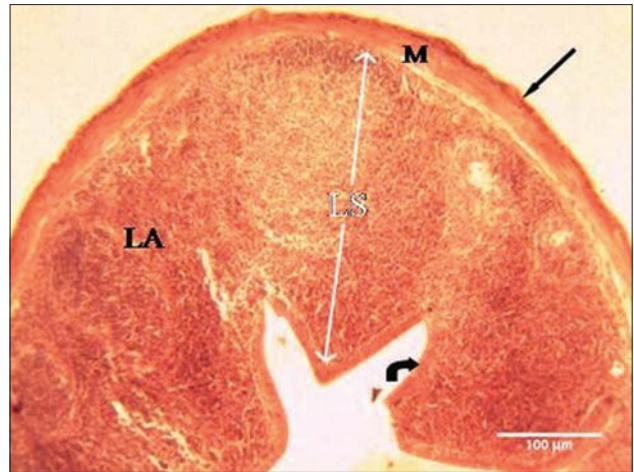


Figure 3: Photomicrograph of the cecum of common pigeon showing the serosa (straight black arrow), tunica muscularis (M), lamina propria-submucosa (LS), and simple columnar epithelium of the tunica mucosa (curved arrow). Note the lymphocytic aggregations (LA) of the lamina propria-submucosa (H and E, x40) scale bar = 100 μm

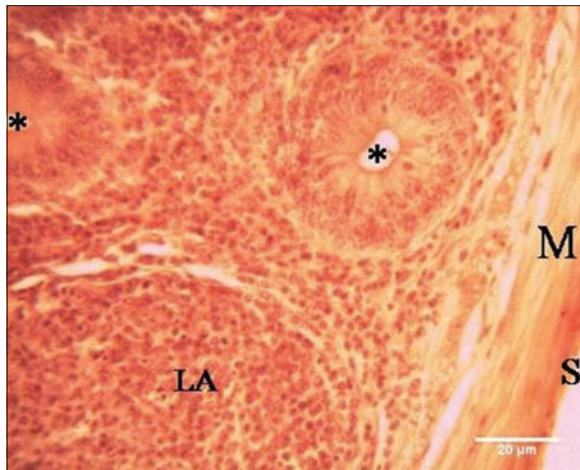


Figure 4: Photomicrograph of the cecum of common pigeon showing connective tissue of the serosa (S), smooth muscle layers of the tunica muscularis (M), the lymphocytic aggregation (LA), and acini of glands (asterisk) of tunica submucosa (H and E, x400) scale bar = 20 μm

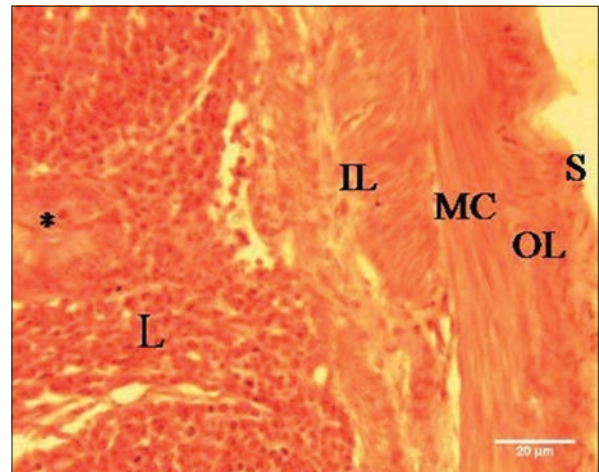


Figure 5: The cecum of common pigeon showing inner longitudinal (IL), middle circular (MC), and outer longitudinal (OL) smooth muscle layers. Note the lymphocytic aggregation (L), glandular acinus (asterisk) and serosa (S) (H and E, x400) scale bar = 20 μm

and habitat of the particular species of bird. The present study illustrates the occurrence of an oblique thickened layer of smooth muscle fibers interposed between the middle circular and outer longitudinal smooth muscle layers of the tunica muscularis of the common pigeon. We postulate that this thickened muscle layer may serve as a sphincter that governs the movement of the ingesta from the distal ileum, into the colorectum; thus, it regulates the passage of materials through the ileo-ceco-rectal orifice and limits the diversion of food particles into the lumen of the ceca. A similar function was ascribed to an ileal papilla located in the terminal part of the ileum of chicken and duck (Clarke, 1978; Mahdi and McLelland, 1988).

The ceca of common pigeon are small in size measuring approximately 0.33 cm in length. The occurrence of similar

small-sized ceca has been reported in other birds including eagle, hawks, African pied crow, vultures, and other prey birds (Naik, 1962; Clench and Mathias, 1995; Igwebuikwe and Eze, 2010). It has been demonstrated that the size of the avian ceca may be influenced by the type of diet consumed by the particular species of bird (Leopold, 1953; Clench and Mathias, 1995; Igwebuikwe and Eze, 2010; Karasov, et al., 2011; Duritys, et al., 2013). Barnes and Thomas (1987) showed that predatory species of birds, with no indigestible carbohydrates in their diet, were characterized with poor cecal development. The presence of glandular acini in the lamina propria-submucosa of the common pigeon's ceca, as demonstrated in this study, indicates that some enzymatic breakdown of food particles may occur in the ceca. Indeed, avian ceca are thought to play a role in microbial degradation of carbohydrates (Rezaian and Hamed, 2007), cholesterol digestion and

absorption (Tortuero *et al.*, 1975), and water re-absorption from feces and urine (Rezaian and Hamed, 2007). However, the small size of the ceca may imply that such intra-cecal digestion is very minimal since most of the free mono- and di-saccharides and amino acids are completely digested and absorbed in the small intestine (Riesenfeld *et al.*, 1980; Southgate, 1995).

Large numbers of lymphoid aggregates characterized the lamina propria-submucosa of the common pigeon's ceca, being present in the basilar, middle, and apical parts of the organ. Lymphoid cells of the avian ceca are important components of the gut-associated lymphoid tissues, composed of several cell types including specialized inducer, immunoregulatory, and effector cells that are distinct from their counterparts in the systemic immune system (Friedman *et al.*, 1994). Accumulation of immune cells in the avian gut has been associated with gut colonization by microflora (Honjo, *et al.*, 1993). Since the large intestine is very much in contact with the external environment and retrograde peristalsis of the colon may occur to improve water re-absorption from feces and urine (Clench, 1999), it has been suggested that such retrograde peristalsis may also serve an immunological purpose: To sample antigen material from the exterior and to present the rectally-derived external material to the immunologically active ceca (Bar-Shira and Friedman, 2005).

CONCLUSION

The morphology of the ceca of the common pigeon supports the idea that the ceca are important in the digestion of food materials and immunological response of the birds to antigens. In addition, passage of the ingesta through the ileo-ceco-rectal orifice may be regulated by the thickened oblique layer of smooth muscle fibers located within the tunica muscularis of the common pigeon's distal ileum.

Financial Support and Sponsorship
Nil.

Conflicts of Interest

There are no conflicts of interest.

REFERENCES

- Barnes G.G., Thomas V.G. (1987). Digestive organ morphology, diet and guild structure of North American Anatidae. *Can J Zool* 65:1812-7.
- Bar-Shira E., Friedman A. (2005). Ontogeny of gut associated immune competence in the chick. *Israel J Vet Med* 60:42-50.
- Cininari M.E., Moyano G.D., Chediack J.G., Caviedes-Vidal E. (2005). Feral pigeons in urban environments: Dietary flexibility and enzymatic digestion. *Rev Chil Hist Nat* 78:267-79.
- Clarke P.L. (1978). The structure of the ileo-caeco-colic junction of the domestic fowl (*Gallus gallus* L.). *Br Poult Sci* 19:595-600.
- Clench M.H., Mathias J.R. (1995). The avian caecum: A review.

- Wilson Bull 107:93-121.
- Clench M.H. (1999). The avian cecum: Update and motility review. *J Exp Zool* 283:441-7.
- Duke G.E. (1986). Alimentary canal. Anatomy, regulation of feeding, and motility. In: Sturkie P.D, editor. *Avian Physiology*. Springer-Verlag, New York, p. 269-88.
- Duritis I., Mugurevics A. (2011). Morphometric parameters of the small and large intestine of Ostrich (*Strythio camelus Var domesticus*) from day 38 of embryonic development to the age of 60 days. *Proceedings of the Latvia University of Agriculture* 26:84-93.
- Duritis I., Mugurevics A., Mancevica L. (2013). Distribution and characterization of the goblet cells in the Ostrich small intestine during pre and posthatch periods. *Vet Zootec* 63:23-8.
- Dziala-Szczepaneczyk E., Wesolowska I. (2008). Morphometric characteristics of esophagus and intestine in tufted ducks (*Aythya fuligula*) wintering on the baltic coastal areas in North-Western Poland. *Electron J Pol Agric Univ* 11:1-35.
- Friedman A., Al-sabbagh A., Santos A.L., Fishman-Lobell J., Polanski M., Das M.P, *et al.* (1994). Oral tolerance: A biologically relevant pathway to generate peripheral tolerance against external and self antigens. *Chem Immunol* 58:259-90.
- Honjo K., Hagiwara T., Itoh K., Takahashi E., Niota Y. (1993). Immunohistochemical analysis of tissue distribution of B and T cells in germfree and conventional chickens. *J Vet Med Sci* 55:1031-4.
- Igwebuie U.M., Eze U.U. (2010). Morphology of the caeca of the African Pied crow (*Corvus albus*). *Anim Res Int* 7:1121-4.
- Jokimati J., Suhonen J. (1998). Distribution and habitat selection of wintering birds in urban environments. *Landsc Urban Plan* 39:253-63.
- Karasov W.H., del Rio C.M., Caviedes-Vidal E. (2011). Ecological physiology of diet and digestive systems. *Annu Rev Physiol* 73:69-93.
- Kasperska D., Kokoszyński D., Korytkowska H., Mistrzak M. (2012). Effect of age and sex on digestive tract morphometry of guinea fowl (*Numida meleagris* L.). *Folia Biol Krakow* 60:45-9.
- Klasing K.C. (1998). *Comparative Avian Nutrition*. CAB International, Wallingford and New York.
- Leopold S. (1953). Intestinal morphology of *Gallinaceous* birds in relation to food habits. *J Wildl Manage* 17:197-203.
- Mahdi A.H., McLelland J. (1988). The arrangement of muscle at the ileo-caeco-rectal junction of the domestic duck (*Anas platyrhynchos*) and the presence of anatomical sphincters. *J Anat* 161:133-42.
- Majeed M.F., Al-Asadi F.S., Nassir A.N., Rahi E.H. (2009). The immunological and histological study of the caecum in broiler chicken. *Basrah J Vet Res* 8:19-25.
- Mot M. (2010). Morphological aspects of digestive apparatus in owl (*Asio flammeus*) and dove (*Columba livia*). *Lueräri Stiinficce Med Vet XLIII: 364-7*.
- Naik D.R. (1962). A Study of the Intestinal Caeca of Some Indian Birds. M.Sc thesis, Banaras Hindu University, Varanasi, India, 1962.
- Parehami A., Dehkordi F.R. (2011). Lingual structure of the domestic pigeon (*Columba livia domestica*): A light and electron microscopic studies. *Middle East J Sci Res* 7:81-6.
- Rezaian M., Hamed S. (2007). Histological study of the caecal tonsil in the caecum of 4-6 months of age white Leghorn chicks. *Am J Anim Vet Sci* 2:50-4.
- Riesenfeld G., Sklan D., Barr A., Eisner U., Hurwitz S. (1980). Glucose absorption and starch digestion in the intestine of the chicken. *J Nutr* 110:117-21.
- Southgate D.A. (1995). Digestion and metabolism of sugars. *Am J Clin Nutr* 62:203S-10S.
- Tortuero F., Brenas A., Riperez J. (1975). The influence of intestinal (ceca) flora on serum and egg yolk cholesterol levels in laying hens. *Poult Sci* 54:1935-8.
- Zaher M., El-Ghareeb A., Hamdi H., AbuAmod F. (2012). Anatomical, histological and histochemical adaptations of the avian alimentary canal to their food habits: I-Coturnix coturnix. *Life Sci* 9:253-75.