

A histomorphologic analysis of pyrethroid pesticide on the cerebrum and cerebellum of adult albino rats

Odokuma Emmanuel Igho, Iteire Kingsley Afoke¹

Department of Human Anatomy and Cell Biology, Delta State University, Abraka, Delta State, ¹Department of Basic Medical Sciences, Achievers University, Owo, Ondo State, Nigeria

Abstract

Introduction: Pyrethroids Pesticide formulations are complex mixtures and some studies have associated their usage to predisposition to some degenerative diseases. This study was therefore aimed at investigating the sub-acute and acute histomorphologic effects of orally administered mixture of Allethrin, Imiprothrin and Phenothrin (P. pesticide) on the cerebrum and cerebellum of adult Wistar rats. **Materials and Methods:** 80 adult Wistar rats of both sexes were divided into 5 groups of 15 rats each. Group I-III which was the treatment groups were further subdivided into 3 groups of 5 rats each while groups IV and V were normal and oil control respectively. The Pesticide was diluted with olive oil into 3 grades (75, 50 and 25% concentration) and orally administered to the rats of the treatment groups for 7, 21 and 40 days. The rats in group IV and V were given water and olive oil respectively for the duration of the treatment. At the end of the treatment, the rats were sacrificed by cervical dislocation. The brains were harvested and processed for histology using standard manual tissue processing techniques. **Results/Discussion:** The behaviors exhibited by the animals included itching, twitch contraction, dilation of pupils, erected furs, tail suspension and increased salivation. Histological examination of the brain tissues revealed mild to marked distortion of the cyto-architectural patterns with multifoci of necrosis, severe gliosis involving predominantly astrocytes and oligodendrocytes both in the cerebral and cerebellar tissues. **Conclusion:** In conclusion, this study showed that oral administration of P. pesticide resulted in several histomorphologic changes in the brain tissues in both dose and time dependent manner.

Key words: Brain, cerebellum, cerebrum, histomorphologic, pyrethroids, Wistar rats.

INTRODUCTION

Pesticides have been described as chemical substances that are used for the eradication of rodents, insects, weeds,

Address for correspondence:

Mr. Iteire Kingsley Afoke,
Department of Basic Medical Sciences, Achievers University, Owo,
Ondo State, Nigeria.
E-mail: kingsleyafoke@yahoo.co.uk

Access this article online	
Quick Response Code:	Website: www.jecajournal.com
	DOI: 10.4103/1596-2393.154401

and unwanted organisms. Although reports by Dr. Alice Larson at a workshop of the United State Environmental Protection Agency (US- EPA) and some other studies have shown that the incessant usage of these chemical substances could adversely affect the health of man and his immediate environment (Larson, 2001, Bassil *et al.*, 2007, Sanborn *et al.*, 2007, Jurewicz and Hanke, 2008), these agents are still being utilized as the major control source for vectors of malaria which has been previously reported by (Soderlund *et al.*, 2002). Humans had been known to be exposed to these agents during manufacturing, packaging, and application or through eating contaminated food and this has led to the increase risks associated with them. Among the classes of pesticides, insecticides have been implicated as having the most effects on human health because they are designed to act on insect receptors, ion channels, and enzymes which are very similar to those found in humans (Gupta, 2006).

Pyrethroids have been discovered to be formulated with petroleum distillates and packaged in combination with synergists such as piperonyl butoxide and n-octyl bicycloheptene dicarboximide (Gosselin, 1984) thereby facilitating their absorption and crossing the blood-brain barrier into the central nervous system (CNS) (Crofton *et al.*, 1995) which could result to nervous tissue damages.

Exposures to some pyrethroids have been recognized in several potentially receptive sub-population including pregnant women, infants, and children to trigger some congenital developmental diseases (Whyatt *et al.*, 2004, Yáñez *et al.*, 2002, Berkowitz *et al.*, 2003, Heudorf *et al.*, 2004). This has led to more precautionous usages of these agents in those settings. Pyrethroids are divided into Type I and Type II pyrethroids based on the absence or presence of a cyano group (Glickman and Casida, 1982). Deltamethrin (DLM) which is a Type II pyrethroid has been reported to have caused signs of acute poisoning, salivation, hyper-excitability, choreo-athetosis, and seizures in test subjects (Soderlund *et al.*, 2002). Similarly, intra-cerebral injection of DLM has been shown to produce signs of neurotoxicity in less than a minute in mice (Lawrence and Casida, 1982), although it was not clear whether these effects caused by this single pyrethroid was observed as histological changes as was determined in this study. According to the reports of (Cantalamessa, 1993) young animals were observed to be more susceptible to the acute neurotoxicity of pyrethroids due to the age-related susceptibility of rat pups to cypermethrin (Type II) and permethrin (Type I). He also proposed in his reports that partial development of detoxification enzymes could be responsible for the age dependence, although his experiments involved the use of mono-oxygenase and esterase inhibitor pretreatments rendering his results inconclusive. Similarly, (Sheets *et al.* 1994) reported in his study that pre-weanling pups were much more vulnerable to acute DLM toxicity than adults, therefore, suggesting that the difference could have resulted from differences in their metabolic activities.

The actions of P pesticide insecticides on nerve membrane have been linked to biological responses resulting from the neurotoxic effects as observed in acute behavioral tests which may involve changes in gene expression (Bradley and Finkbeiner, 2002, Clayton, 2000, Adams and Dudek, 2005). Such biological responses have been associated with the development of cancer of the blood, brain, kidney, breast, prostate, pancreas, liver, lungs, skin, nonHodgkin lymphoma and lymphoma as reported by (Larson, 2001, Bassil *et al.*, 2007, Sanborn *et al.*, 2007, Jurewicz and Hanke, 2008). The recent increases of these chronic diseases as reported by (Sanborn *et al.*, 2007) have led to the investigation of the effects of other types of these agents on the nervous system as being carried out in this study. The

pyrethroids (P) pesticide used for this experiment was made up of the following active ingredients: d-trans allethrin (0.10%w/w), imiprothrin (0.02% w/w), and d-phenothrin (0.03% w/w) and there had been a dearth of information about the toxicity of this mixture. Furthermore, information gotten from the products facts sheets suggested that chronic studies have not been carried out about this product, hence, additional studies are needed to clarify the effects of repeated oral administration of the product on nervous system function and cognition of adult Wistar rats. This study was, therefore, aimed at determining the sub-acute and acute toxicities of P pesticide in the cerebrum and cerebellum of adult Wistar rats.

MATERIALS AND METHODS

Materials

Experimental animals

The study involved the use of 80 adult Wistar rats of both sexes (40 male and 40 female) that was obtained from the animal facility of the College of Health Sciences, Delta State University Abraka. The animals were in good physical condition weighing 150–250 g. The rats were kept in an iron cage with compartments and allowed to acclimatize for 2 weeks under favorable climatic conditions. They were fed with standard rat pellets and water *ad libitum*.

Pyrethroids pesticide (allethrin, imiprothrin, and phenothrin)

These chemicals product which was manufactured by Rekind Benckiser Nigeria Limited, Agbara Ogun State, and registered with National Agency for Food and Drug Administration Control number 048724 was purchased from a local store in Abraka, Ethiope-East Local Government Area of Delta State and used for the experiment.

Experimental design modified from Nair et al., 2010.

The rats were randomly assigned into five groups containing 15 animals each and kept in separate compartments. Groups' I-III was treatment Groups while IV and V were normal and oil control groups respectively. Groups' I-III was further subdivided into three subgroups, respectively, each of five animals. Since pyrethroids are lipophilic, Goya olive oil was used to dilute the pesticide into three grades (of 25, 50 and 75% concentration). The rats in Group Ia, IIa, and IIIa were treated with 3 ml/kg/bw of 75%, Ib, IIb, and IIIb with 3 ml/kg/bw of 50% while those in Ic, IIc, and IIIc were treated with 3 ml/kg/bw of 25% of the agent orally via an improvised plastic cannula for a duration of 7, 21 and 40 days each. Group four was given 3 ml/kg/bw of tap water as placebo while group five received 3 ml/kg of the diluent throughout the duration off the experiment.

Animal behavioral study

After the daily administration of the chemicals to the animals, behaviors such as aggressiveness, suspended tail, erected furs, drowsiness, itching, and feeding patterns were observed and recorded for up to 2 h postadministration.

Methods of Sample Collection

At the end of the treatment (days 7, 21, and 40, respectively), the animals were sacrificed by cervical dislocation, then the brains were harvested and prepared for histological examination under the light microscopy for identification of any histomorphological changes. The procedures following for the preparation of the brain sections were as follows: The brains were harvested and fixed in neutral buffered formalin for about 48 h after which the cerebrum and cerebellum were identified and cut into thinner slices (3–5 mm thick). The tissues were processed for histology using standard manual tissue processing techniques. Sections of about 3–5 μm were cut by a SLEE Medical rotary microtome, stained with hematoxylin and eosin and examined under light microscope (Carlton, 1967). The slides were viewed and captured on a Brunel light microscope (Brunel SP35 Digital Trinocular).

Ethical clearance

Approval for this study was obtained from the Research Ethics Committee of the Department of Human Anatomy and Cell Biology, Delta State University Abraka protocol number: DELSU/BMS/ANA/12/13/0012 and the experiment was carried out in strict accordance with the guidelines for the care and use of animals for research.

RESULTS

Table 1 shows behaviors that the animals exhibited due to the effects of the agent. 0% of the rats in all groups behaved aggressively although 100% of the ones treated exhibited suspended tails which suggested that the agent

was an antidepressant. 75% of the treated rats had erected furs which also suggested their activeness. More than 90% of the rats did not show any sign of drowsiness but their feeding habit reduced initially probably due to the irritations caused by the chemical. After the 1st week their feeding habit became normal (100%) of the treated rats exhibited itching which was a common sign of irritation and increased bowel movement which may be due to increased intestinal motility as a result of the effect of the olive oil used as a vehicle for the chemical. Pupil dilation occurred in 40% of the treated rats while 2% of them experienced staggering gait which subsided as the experiment lasted.

Histological Effects of Pyrethroids Pesticides on the Cerebrum and Cerebellum

Control rats brain

Figure 1 shows a section of the rat brain composed of both cerebral and cerebella tissues. The cerebral tissues were composed of neurons disposed within abundant glial tissue foci of nuclei composed of unipolar giant cells. The cerebella tissue was composed of molecular, purkinje and

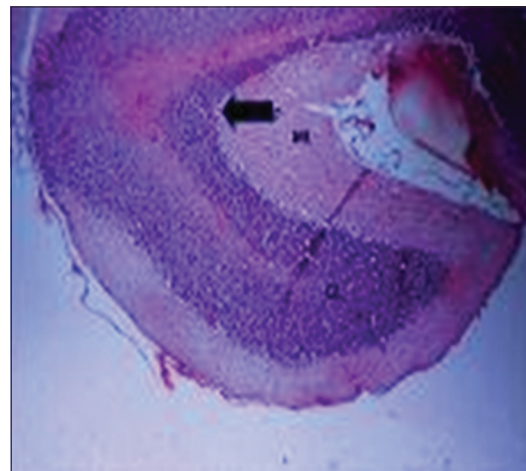


Figure 1: Sections of a rat brain from the normal control group; P - Purkinje layer, ML - Molecular layer, GL - Granular layer (H and E, ×100)

Table 1: Animal behavioral response table

Groups	Sub-group	Aggressiveness	Suspended tail	Erected furs	Drowsiness	Itching	Feeding	Increased bowel movement
1	D	Absent	Present	Present	Absent	Present	Decreased feeding	Present
	E		Present	Present	Absent	Present	Decreased feeding	Present
	F	Absent	Absent	Absent	Absent	Absent	Normal	Absent
2	X	Absent	Present	Present	Absent	Present	Decreased feeding	Present
	Y	Absent	Present	Absent	Absent	Present	Decreased feeding	Present
	Z	Absent	Absent	Absent	Absent	Absent	Normal	Absent
3	A	Absent	Present	Present	Absent	Present	Normal	Present
	B	Absent	Present	Present	Absent	Present	Normal	Present
	C	Absent	Absent	Absent	Absent	Absent	Normal	Present
4	Control	Absent	Absent	Absent	Absent	Absent	Normal	Present
5	G	Absent	Absent	Absent	Absent	Absent	Normal	Present
	M	Absent	Absent	Absent	Absent	Absent	Normal	Present
	N	Absent	Absent	Absent	Absent	Absent	Normal	Present

granular cortical layer and a central layer of grey matter. Within this central core of white matter were sparse nuclei of grey matter. The features were in keeping with normal rat brain architecture.

Treated rats brains

Figure 2 shows a section of the rat cerebella tissue composed of outer white matter which was composed of a molecular, purkinje, granular layer, and an inner grey matter. The tissue had abundant gliosis (black double arrow) especially in the middle white matter. The predominant glial cells were astrocytes. A nucleolus composed of molecular giant cells (g) was seen in this section. The features were in keeping with acute gliosis.

Figure 3 shows a section of the rat brain composed of cerebral tissue containing neuronal cells disposed within areas of glial tissue. Convolutions of cerebella cortex and medulla were also seen. Foci of a moderate gliosis (red curve double arrow connector) were present. The features were in keeping with moderate gliosis.

Figure 4 shows a section of the rat brain composed of cerebral tissue composed of an outermost grey matter, middle white matter and the innermost grey matter. There was extensive enlargement of the granular aspect of the outermost white matter and marked proliferation of astrocyte and oligodendrocytes within the inner white matter layer. The astrocytes were disposed in bands (black double arrow connectors). Also seen were clusters of choroid plexus (red up arrow) and blood vessels (green left arrow). These features were in keeping with marked chronic gliosis.

Figure 5 shows a section of the rat brain composed of both cerebral and cerebella tissues. The cerebral tissue was composed of neurons disposed within abundant glial tissue. Foci of nuclei composed of unipolar giant cells were seen. The cerebella tissue was composed of molecular (m), purkinje (p) and granular cortical layer (g) and a central layer of grey matter. Within this central core of white matter were sparse nuclei of grey matter shows normal architectural pattern. However,

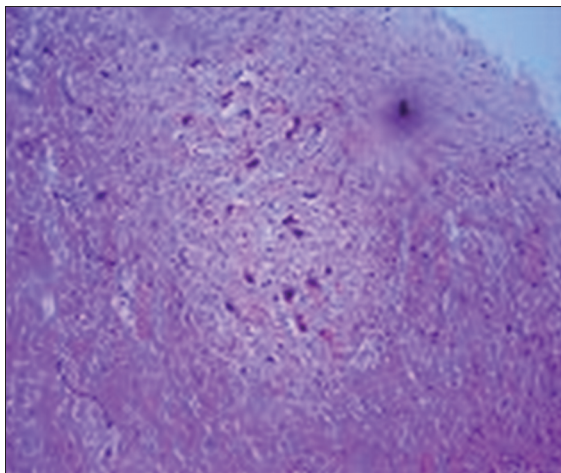


Figure 2: Sections from a rat brain treated with 75% 'M' pesticide (3 ml/kg) for 7 days; G - Giant cell (H and E, ×100)

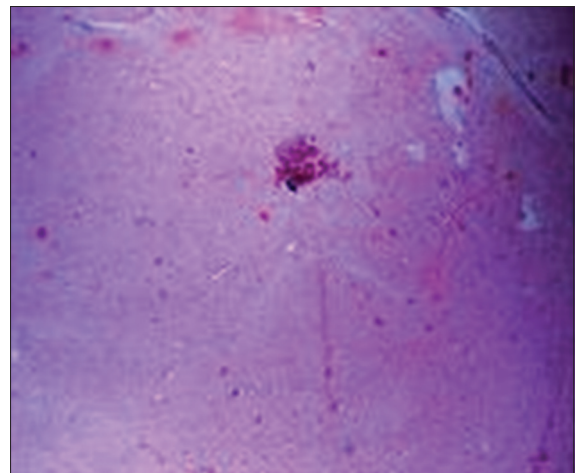


Figure 3: Sections of a rat brain treated with 75% 'M' pesticide (3 ml/kg) for 21 days (H and E, ×100)

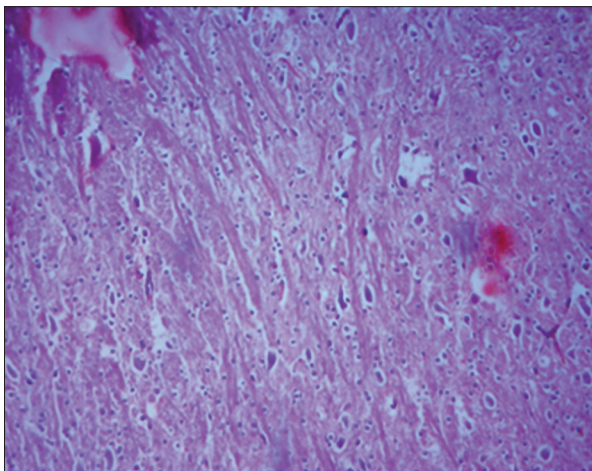


Figure 4: Sections of a rat cerebellum treated with 75% 'M' pesticide (3 ml/kg) for 40 days (H and E, ×100)

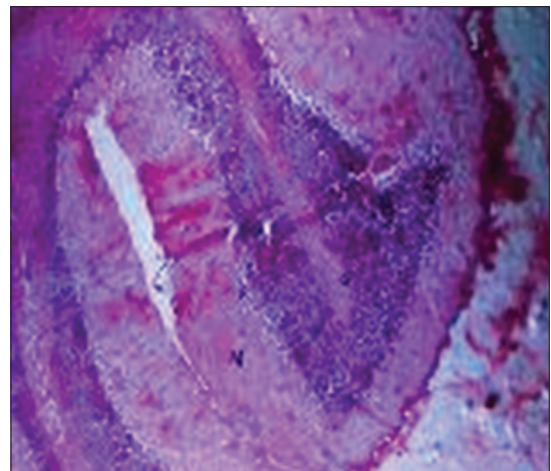


Figure 5: Sections of a rat cerebrum and cerebellum treated with 50% 'M' pesticide (3 ml/kg) for 7 days (H and E, ×100)

there was distortion of the cyto-architectural pattern (red curve double arrow connector) with multifoci of the necrosis (black curve double arrow connector). The features were in keeping with mild gliosis.

Figure 6 shows a section of the rat brain composed of cerebral tissue containing neuronal cells disposed within areas of glial tissue. Convolutions of cerebella cortex and medulla were also seen. Foci of a moderate gliosis (white curve double arrow connector) were present. The features were in keeping with moderate gliosis.

Figure 7 shows section of the rat brain composed of variably sized neurons disposed within glia tissues. A portion of the cerebellum and peduncle were seen. Bulbs of glial cell processes were prominent in the sections of this tissue. There was marked gliosis (black double arrow connector) within the cerebral tissues consisting of predominantly oligodendrocytes. The features were in keeping with marked oligodendroglia.

Figure 8 shows a section of the rat brain composed of cerebral and cerebellar tissues. There was foci of moderate gliosis within the cerebral tissue (red curve double arrow connector) involving predominantly oligodendrocytes. A few or scant foci of necrosis (black arrow) were also present within the cerebral tissue. The features were in keeping with oligodendroglia.

DISCUSSION

Information based on the findings of (World Health Organization, 1997) on the evaluation of insecticides has suggested that the major means of fighting malaria was by vector control. This has led to the high increase in the use of domestic insecticides in controlling these vectors in our homes. This study however revealed that these agents were associated with extensive cerebellar and cerebral damage with marked and impaired behavioral changes. These findings were similar to the observations made by (Aldridge 1990) in which tremors, pawing, salivations, and seizures were observed in rats administered with P. pesticide. He further suggested that these behaviors were a result of excitation of the peripheral nervous system by the agent. It is likely that the damage to the central nervous tissue could have resulted in the obscure changes as these agents are known to easily penetrate the blood-brain barrier with resultant severe neurotoxic effects on animals (Latuszynska *et al.*, 1996).

Furthermore, the effects as observed by the behavioral changes in the animals were reflected by gliosis which was severely marked in the cerebellar and cerebral tissues of animals administered the higher doses and longer durations suggesting a dose and time-dependence effects

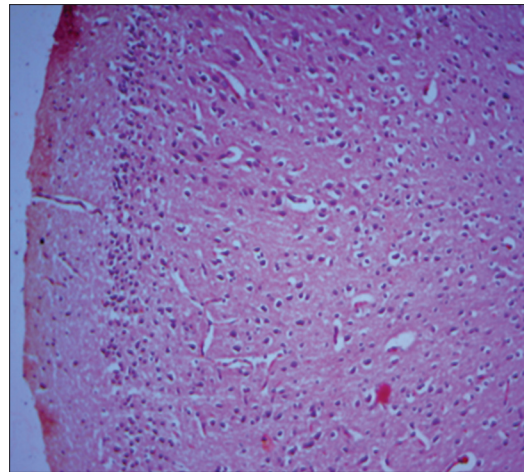


Figure 6: Sections of a rat brain treated with 50% 'M' pesticide (3 ml/kg) for 21 days (H and E, ×100)

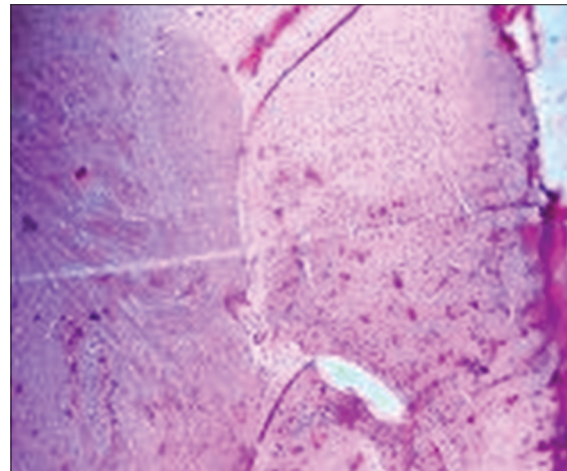


Figure 7: Sections of a rat brain treated with 50% 'M' pesticide (3 ml/kg) for 40 days (H and E, ×100)

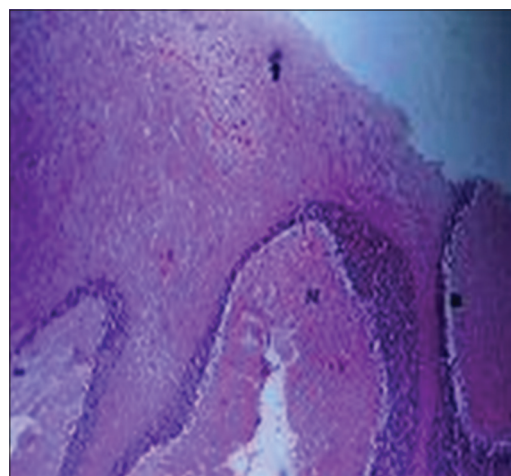


Figure 8: Sections of rat brain tissue treated with 25% 'M' pesticide (3 ml/kg) for 7 days (H and E, ×100)

on the CNS tissues. However gliosis has previously been described by (Fawcett and Asher, 1999) as non-specific changes of glial tissues to CNS injuries such as reported

in Alzheimer disease, Korsakoff's syndrome, Multiple system atrophy, Prion disease, multiple sclerosis, and Huntington disease. Most of these changes usually involve the extensive proliferation of astrocytes, microglia, and oligodendrocytes leading to the formation of a glial scar that can impair a normal neuronal conduction in the nervous system (Fawcett and Asher, 1999). These findings were also similar to those reported by (Gupta, 2006, Grewal *et al.*, 2010, EL-Bendary *et al.*, 2004) in which gliosis was observed in rats administered with P pesticide.

Other features observed in this study were distorted cyto-architectural patterns and presence of multifoci of necrosis in the cerebellar and cerebral tissues. These features may have resulted from the death of these tissues as reported by (Nair *et al.*, 2010, Manna *et al.*, 2004, Latuszynska *et al.*, 2001, Luty *et al.*, 2007).

CONCLUSION

In our present study, oral administration of P pesticide at different doses resulted in significant histomorphological changes in the cerebral and cerebella tissues investigated, therefore special safety measures (or total avoidance) should be employed in the usage of these agents as domestic insecticides.

REFERENCES

- Larson A (2001). U.S. Environmental Protection Agency Pesticides: Health and Safety. National Assessment of the Worker Protection Workshop #3.
- Bassil K.L., Wakil C., Sanborn M., Cole D.C., Kaur J.S., Kerr K.J. (2007). Cancer health effects of pesticides: Systematic review. *Can Fam Physician* 53 (10):1704-11.
- Sanborn M., Kerr K.J., Sanin L.H., Cole D.C., Bassil K.L., Wakil C. (2007). Non-cancer health effects of pesticides: Systematic review and implications for family doctors. *Can Fam Physician* 53 (10):1712-20.
- Jurewicz J., Hanke W. (2008). Prenatal and childhood exposure to pesticides and neurobehavioral development: Review of epidemiological studies. *Int J Occup Med Environ Health* 21 (2):121-32.
- Soderlund D.M., Clark J.M., Sheets L.P., Mullin L.S., Piccirillo V.J., Sargent D., *et al.* (2002). Mechanisms of pyrethroid neurotoxicity: Implications for cumulative risk assessment. *Toxicology* 171 (2):3-59.
- Gupta R.C., (2006). Classification and uses of Organophosphate and Carbamate Compounds. Gupta RC (ed.), Academic press/ Elsevier, Amsterdam. 5-24.
- Gosselin R.E. (1984). *Clinical Toxicology of Commercial Products*. Williams and Wilkins, Baltimore, MD.
- Crofton K.M., Kehn L.S., Gilbert M.E. (1995). Vehicle and route dependent effects of a pyrethroid insecticide, deltamethrin, on motor function in the rat. *Neurotoxicol Teratol* 17 (4):489-95.
- Whyatt R.M., Rauh V., Barr D.B., Camann D.E., Andrews H.F., Garfinkel R., *et al.* (2004). Prenatal insecticide exposures and birth weight and length among an urban minority cohort. *Environ Health Perspect* 112 (10):1125-32.
- Yáñez L., Ortiz-Pérez D., Batres L.E., Borja-Aburto V.H., Diaz-Barriga F. (2002). Levels of dichlorodiphenyltrichloroethane and deltamethrin in humans and environmental samples in malarious areas of Mexico. *Environ Res* 88 (3):174-81.
- Berkowitz G.S., Obel J., Deych E., Lapinski R., Godbold J., Liu Z., *et al.* (2003). Exposure to indoor pesticides during pregnancy in a multiethnic, urban cohort. *Environ Health Perspect* 111 (1):79-84.
- Heudorf U., Angerer J., Drexler H. (2004). Current internal exposure to pesticides in children and adolescents in Germany: Urinary levels of metabolites of pyrethroid and organophosphorus insecticides. *Int Arch Occup Environ Health* 77 (1):67-72.
- Glickman A.H., Casida J.E. (1982). Species and structural variations affecting pyrethroid neurotoxicity. *Neurobehav Toxicol Teratol* 4 (6):793-9.
- Lawrence L.J., Casida J.E. (1982). Pyrethroid toxicology: Mouse intracerebral structure-toxicity relationships. *Pestic Biochem Physiol* 18:9-14.
- Cantalamesa F. (1993). Acute toxicity of two pyrethroids, permethrin, and cypermethrin in neonatal and adult rats. *Arch Toxicol* 67 (7):510-3.
- Sheets L.P., Doherty J.D., Law M.W., Reiter L.W., Crofton K.M. (1994). Age-dependent differences in the susceptibility of rats to deltamethrin. *Toxicol Appl Pharmacol* 126 (1):186-90.
- Bradley J., Finkbeiner S. (2002). An evaluation of specificity in activity-dependent gene expression in neurons. *Prog Neurobiol* 67 (6):469-77.
- Clayton D.F. (2000). The genomic action potential. *Neurobiol Learn Mem* 74 (3):185-216.
- Adams J.P., Dudek S.M. (2005). Late-phase long-term potentiation: Getting to the nucleus. *Nat Rev Neurosci* 6 (9):737-43.
- Nair R.R., Abraham M.J., Nair N.D., Lalithakunjamma C.R., Aravindakshan C.M. (2010). Hematological and biochemical profile in sublethal toxicity of cypermethrin in rats. *Int J Biol Med Res* 1:211-4.
- Carlton S.M. (1967). *Text Book of Histochemical Techniques*. 4th ed. Oxford University Press, Ely House, London W.I, 48-137.
- World Health Organization. (1997). Assessment of Exposure to Indoor Air Pollutants. Technical Report Number. WHO Regional Publications European, WHO, Copenhagen, Denmark.
- Aldridge W.N. (1990). An assessment of the toxicological properties of pyrethroids and their neurotoxicity. *Crit Rev Toxicol* 21 (2):89-104.
- Latuszynska J., Luty S., Halliop J., Przylepa E., Tochman A., Obuchowska D., *et al.* (1996). Studies of toxicity of dermally-absorbed nurelle D 550 EC preparations. *Ann Agric Environ Med* 6 (2):151-9.
- Fawcett J.W., Asher R.A. (1999). The glial scar and central nervous system repair. *Brain Res Bull* 49 (6):377-91.
- Grewal K.K., Sandhu G.S., Kaur R., Brar R.S., Sandhu H.S. (2010). Toxic impacts of cypermethrin on behavior and histology of certain tissues of albino rats. *Toxicol Int* 17 (2):94-8.
- EL-Bendary H.M., Shaker M.H., Saleh A.A., Negm S.E. (2004). Histopathological changes associated with exposure of male mice to profenofis and chlorpyrifos. *Ann Res Rev Biol* 4:2347-565.
- Manna S., Bhattacharyya D., Basak D.K., Mandal T.K. (2004). Single oral dose toxicity study of α -cypermethrin in rats. *Indian J Pharmacol* 36:25-8.
- Latuszynska J., Luty S., Raszewski G., Tokarska-Rodak M., Przebirowska D., Przylepa E., *et al.* (2001). Neurotoxic effect of dermally-applied chlorpyrifos and cypermethrin in Wistar rats. *Ann Agric Environ Med* 8 (2):163-70.
- Luty S., Latuszynska J., Obuchowska-Przebirowska D., Tokarska M., Haratym-Maj A. (2007). Subacute toxicity of orally applied alpha-cypermethrin in Swiss mice. *Ann Agric Environ Med* 7 (1):33-41.

How to cite this article: Igho OE, Afoke IK. A histomorphologic analysis of pyrethroid pesticide on the cerebrum and cerebellum of adult albino rats. *J Exp Clin Anat* 2014;13:54-9.

Source of Support: Nil, **Conflict of Interest:** None declared.