

# Ameliorative effect of ascorbic acid on mercury chloride-induced changes on the spleen of adult wistar rats

Augustine Oseloka Ibegbu, Ayuba Micheal, A.Animoku Abdulrazaq, Brosu Daniel, A.Adamu Sadeeq, Akpulu Peter, W. O. Hamman, U. E. Umana, S.A. Musa

Department of Human Anatomy, Faculty of Medicine, Ahmadu Bello University Zaria, Zaria, Kaduna State, Nigeria

## Abstract

**Introduction:** Mercury is a highly toxic metal that exerts its adverse effects on the health of humans and animals through air, soil, water and food. **Aim:** The present study was aimed at the evaluation of the effects of ascorbic acid on mercury chloride-induced changes on the histomorphology of the spleen of adult Wistar Rats. **Method:** Thirty adult Albino Wistar Rats of average weight of 200g were randomly divided into six groups of five rats per group. The animals were orally administered with different concentrations of mercury chloride daily for three weeks. Group one was administered with normal saline, Group two and three were administered with 52mg/kg body weight and 26.25mg/kg body weight of mercury chloride respectively while Groups four and five were administered with 52mg/kg of mercury chloride and 5mg/kg of ascorbic acid and 26.25mg/kg of mercury chloride and 5mg/kg of ascorbic acid respectively and Group 6 was administered 5mg/kg of ascorbic acid only. After three weeks of administration, the animals were sacrificed, blood and tissue samples were collected for tissue processing and analysis. **Results:** The results showed histo-morphological changes in the spleen of the rats. These changes were shown to be concentration dependent. **Conclusion:** Ascorbic acid administration was able to ameliorate mercury-induced changes in the spleen of adult Wistar rats.

**Key words:** Ascorbic acid, histomorphology, mercury chloride, spleen, Wistar rats

## INTRODUCTION

Man in his environment has been exposed to potential hazard of heavy metals through bioaccumulation and biomagnifications which has been transferred

### Address for correspondence:

Dr. Augustine Oseloka Ibegbu,  
Department of Human Anatomy, Faculty of Medicine, Ahmadu Bello  
University Zaria, Zaria, Kaduna State 81006, Nigeria.  
E-mail: aoibegbu@yahoo.com

to man via food chain as a result of anthropogenic activities (Ghosh and Sil, 2008). Mercury is a heavy metal that is toxic and has led to many health problems in the world. Mercury (Hg) is a highly toxic metal that results in a variety of adverse neurological, renal, respiratory, immune, dermatological, reproductive, and developmental disorders (Risher and Amler, 2005; Senese, 2007). Its wide industry related effects on human and animal bio systems have been well documented (Kurl *et al.*, 2002; WHO, 2004) and general exposure to this biologically-active chemical agent has been shown to be exacerbated through contaminated water and food (Magos and Clarkson, 2006; Son *et al.*, 2010). Nowadays, large population worldwide are exposed to relatively low levels of Hg, especially via the use of pesticides in agriculture and of fluorescent light bulbs as well (El-Shenawy and Hassan, 2008). In this context, Hg exists in a wide variety of physical and chemical states, each of which has specific characteristics for target organs (Aleo *et al.*, 2002; Ghosh and Sil, 2008). For example, exposure to Hg vapor as well

### Access this article online

#### Quick Response Code:



Website:  
[www.jecajournal.com](http://www.jecajournal.com)

DOI:  
10.4103/1596-2393.154402

as to organic Hg compounds specifically affects the central nervous system (Vahter *et al.*, 2000), while kidneys, liver and gastrointestinal tract are mainly targeted by inorganic mercury (Schurz *et al.*, 2000; Ghosh and Sil, 2008).

The spleen is a secondary lymphoid organ present in all vertebrates in which the parenchyma is divided into white pulp (WP) and red pulp (RP) distinguished by different colors. The WP contains dense and highly organized accumulations of B and T lymphocytes around arterioles, while most of the RP consists of blood-filled spaces. These RP spaces are composed of two structures, the arterioles and veins forming the splenic sinuses (Brunet *et al.*, 1993). It has been shown that kidneys contained the largest residues of mercury, followed by liver, spleen, intestine, lymph node, skeletal muscles, lungs, heart, brain and the omental fat, and the intensity of the cytotoxic changes in the various organs was proportional to the amount of mercury accumulated (Pathak and Bhowmik, 1998). It has also been found that subchronic exposure to mercuric chloride resulted in a transient decrease of the lymphoid cell ratio which affected the incidence of splenic T-cell subsets (Brunet *et al.*, 1993). The B-cell population in spleen and maturation patterns of B-cells in bone marrow appeared to be unaffected by the mercury exposure (Brunet *et al.*, 1993; Verma and Waldschmidt, 2007; Badano *et al.*, 2013).

Vitamin C or Ascorbic acid is an essential nutrient for humans and certain other animal species. In living organisms, ascorbate acts as an antioxidant by protecting the body against oxidative stress (Padayatty *et al.*, 2003). According to the Food Standard Agency United Kingdom, it is also a cofactor in at least eight enzymatic reactions including several collagen synthetic reactions that when dysfunctional, cause the most severe symptoms of scurvy (FSAUK, 2007). In animals, these reactions are especially important in wound-healing and in preventing bleeding from capillaries.

Ascorbate is required for a range of essential metabolic reactions in all animals and plants. It is made internally by almost all organisms although there are notable mammalian group exceptions exist. Ascorbic acid is not synthesized by some species of birds and fish. All species that do not synthesize ascorbate require it in their diet. Deficiency in this vitamin causes the disease scurvy in humans and it is widely used as a food additive (Levine *et al.*, 2000; Higdon, 2006). Studies indicate that more than 40% of older individuals in the U.S. take Vitamin C supplements; and in some regions of the country, almost 25% of all adults, regardless of age, take Vitamin C (Carr and Frei, 1999). The aim of the study was to determine the effect of ascorbic acid on mercury chloride-induced changes on the histomorphology of the spleen of adult Wistar rats.

## MATERIALS AND METHODS

### Experimental Animals

Thirty adult Wistar rats of average weight of 200 g were used for this study and were acclimatized for 3 weeks to enable the rats adapt to the laboratory conditions and were kept in the animal house of the Department of Human Anatomy Ahmadu Bello University Zaria. After acclimatization, the rats were divided into six groups of five rats per group for the experiment.

### Experimental Chemicals

Twenty grams of Mercury chloride manufactured by May and Bakers Chemical Laboratory Limited Dagenham England was purchased from Steeve Moore Chemical Co., Ltd., Sokoto Road Zaria, Kaduna State Nigeria. Hundred percent pure Vitamin C tablets manufactured by Jopan Pharmaceuticals Ltd., was purchased from Beautiful Gate Pharmacy Ltd., Samaru Zaria, Kaduna State Nigeria. The mercury chloride used for the experiment was of the approved Laboratory grade chemical by Standard Organization of Nigeria, marketed and sold in Nigeria while the Vitamin C tablets was approved by National Agency for Food and Drug Administration and control to be marketed and used in Nigeria.

### Experimental Protocol

The animals in Group 1 (control) were administered with distilled water, Group 2 was given 52.5 mg/kg body weight of mercury chloride (Hg), Group 3 animals were administered with 26.25 mg/kg body weight of Hg, corresponding to 25% and 12.5% of LD<sub>50</sub> of Hg respectively (Lucky, 1987). Animals in Group 4 were given 52.5 mg/kg body weight of Hg and 5 mg/kg body weight of ascorbic acid, while Group 5 animals were administered with 26.25 mg/kg body weight of Hg and 5 mg/kg body weight of ascorbic acid and Group 6 rats were administered with 5 mg/kg body weight of ascorbic acid only corresponding to 10% of LD<sub>50</sub> of ascorbic acid (FSAUK, 2007). The administration was by oral route daily and lasted for 3 weeks while animal feed and drinking water was allowed *ad libitum*.

### Animals Sacrifice

After the administration, the animals were weighed and anaesthetized by inhalation of chloroform in the sacrificing chamber. Incision was made through the skin of the abdominal wall. The abdomen was opened through a mid-sagittal incision and the spleen was removed and fixed in Bouin's fluid for best fixation of soft tissues. The tissues were routinely processed and stained using hematoxylin and eosin and crystal violet methods (Bancroft and Gamble, 2008).

### Estimation of Hematological Parameters

Blood was collected in the morning by means of

Cardiac puncture and blood cell count was done using an auto-analyzer. Red blood cell (RBC) count, mean corpuscular hemoglobin, mean corpuscular hemoglobin concentration, platelet count, white blood cell count (WBC), packed cell volume (PCV) were analyzed and differential WBC count was done.

### Estimation of Oxidative Parameters

#### Determination of catalase activity

Catalase activity was determined using the method described by Sinha, (1972) and the absorbance was read at 570 nm. Standard curve was made by plotting the absorbance obtained at various levels of the assay. The catalase activity was obtained from the graph of the standard curve.

#### Determination of superoxide dismutase activity

Superoxide dismutase (SOD) activity was determined by a method described by Fridovich, (1989). Absorbance was measured every 30 s up for a total of 150 s at 480 nm from where the SOD activity was calculated.

### Assessment of Lipid Peroxidation

Lipid peroxidation (LPO) as evidenced by the formation of thiobarbituric acid reactive substances was measured by the method of Niehaus and Samuelson (1968). The absorbance of the pink supernatant was measured against a reference blank using a spectrophotometer at 535 nm.

### Assay of Reduced Glutathione Concentration

Reduced glutathione concentration measurements were done according to the method of Ellman (1959) as described by Rajagopalan *et al.* (2004), and the absorbance was read at 412 nm.

### Ethical Approval

Ethical approval was sort and obtained from the Ahmadu Bello University Zaria Ethical Committee after the presentation and successful defense of the Research proposal with No ABUEC13027.

### Statistical Analysis

All data were presented as mean  $\pm$  standard deviation for

establishing significant differences; data were analyzed by one-way analysis of variance, followed by Tukey *post-hoc* test. Values were considered statistically significant if  $P \leq 0.05$ .

## RESULTS

### Physical Observation of the Animals

During the period of administration, the animals were observed to be using their forelimbs to scratch their mouth following mercury chloride administration, the animals showed sign of weakness and reduction of their physical activities. The result showed decrease in body weight in animals administered with mercury chloride, while there was increase in the body weight in the control and Group 6 animals that were treated with Vitamin C only.

### Hematological Indices

The result of hematological analyses showed that there was a general decrease in hematological parameters; PCV, hemoglobin (Hb), WBC, and White Cell Volume (WCV) in the group treated with mercury chloride as shown in Table 1.

### Oxidative Parameters

The result of the analysis of oxidative stress markers namely catalase, SOD, glutathione reductase and LPO following administration of mercury chloride and ascorbic acid showed increase and decrease in some parameters as shown in Table 1. The result showed a significant decrease ( $P < 0.05$ ) in catalase, SOD and glutathione reductase in Groups 2, 3, and 4 when compared with the control, and a significant increase ( $P < 0.05$ ) in lipid peroxidase in Groups 2 and 3, and a significant decrease ( $P < 0.05$ ) in Groups 5 and 6 when compared with the control as shown in Table 2.

### Histological Studies

The result of histological observations of the spleen of the experimental animals, showed histological changes in the rats administered with different doses of mercury chloride with or without Vitamin C. The result from the control (Group 1) showed normal tissue arrangement and cells of the spleen. While the

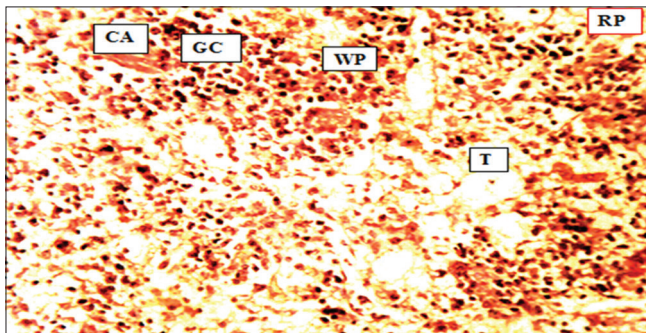
**Table 1: Effect of ascorbic acid administration on mercury chloride-induced changes on the hematological parameters of adult Wistar rats**

Group	Mean $\pm$ SEM						
	PCV (1/L)	Hb (g/L)	RBC ( $\times 10^{12}/L$ )	WBC ( $\times 10^9/L$ )	MCHC (g/L)	MCV (fL, $10^{-5}$ L)	MCH (pg, $10^{-12}$ g)
I	0.432 $\pm$ 0.01	14.42 $\pm$ 0.30	5.92 $\pm$ 0.24*	6.22 $\pm$ 0.52*	33.37 $\pm$ 0.02	0.08 $\pm$ 0.0*	2.44 $\pm$ 0.13
II	0.407 $\pm$ 0.02	13.53 $\pm$ 0.62	4.73 $\pm$ 0.27*	3.97 $\pm$ 0.15*	33.23 $\pm$ 0.33	0.09 $\pm$ 0.01	2.86 $\pm$ 0.23
III	0.420 $\pm$ 0.12	14.00 $\pm$ 0.40	5.03 $\pm$ 0.58	8.18 $\pm$ 0.65	33.35 $\pm$ 0.29	0.09 $\pm$ 0.01	2.93 $\pm$ 0.43
IV	0.40 $\pm$ 0.15	13.33 $\pm$ 0.51	5.93 $\pm$ 0.18*	6.63 $\pm$ 0.67*	33.30 $\pm$ 0.04	0.07 $\pm$ 0.00*	2.25 $\pm$ 0.07
V	0.42 $\pm$ 0.02	13.83 $\pm$ 0.62	5.70 $\pm$ 0.48	7.10 $\pm$ 0.48	33.28 $\pm$ 0.05	0.07 $\pm$ 0.00	2.45 $\pm$ 0.12
VI	0.39 $\pm$ 0.01	12.90 $\pm$ 0.25	4.08 $\pm$ 0.37*	6.90 $\pm$ 0.61*	33.30 $\pm$ 0.04	0.09 $\pm$ 0.01*	3.28 $\pm$ 0.38

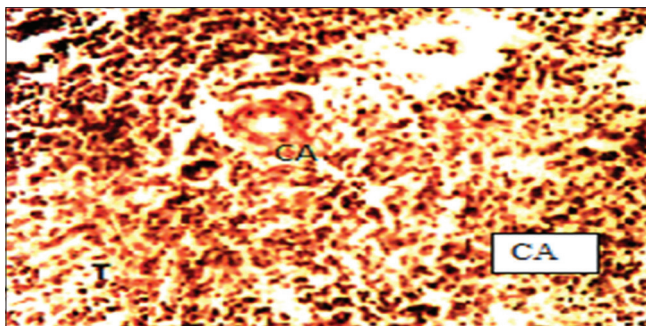
\* $P < 0.05$ . RBC - Red blood cell, WBC - White blood cell, PCV - Packed cell volume, Hb - Hemoglobin, MCHC - Mean corpuscular hemoglobin concentration, MCH - Mean corpuscular hemoglobin, MCV - Mean corpuscular volume, SEM - Standard error of the mean



spleen of the rats in the treated Groups manifested with several histomorphological changes. Group 1 showed normal cyto-architecture of the spleen with normal trabeculae, central artery (CA), and normal germinal disc as shown in Figure 1. Group 2 showed gross changes in the spleen, characterized by swelling, mononuclear infiltration, congestion, hemorrhage, and vacuolization of germinal center as shown in Figure 2. Group 3 showed congested CA, degeneration of the spleen cells are less severe as shown in Figure 3. Group 4 showed necrosis of cells evident by karyolysis and pyknosis, sparsely packed cells, and CA was not evident with normal RP as shown in Figure 4. Group 5 showed severe degeneration of the layers of spleen as shown in Figure 5. While Group 6 showed normal cyto-architecture of the spleen which are similar to the control Group as shown in Figure 6.



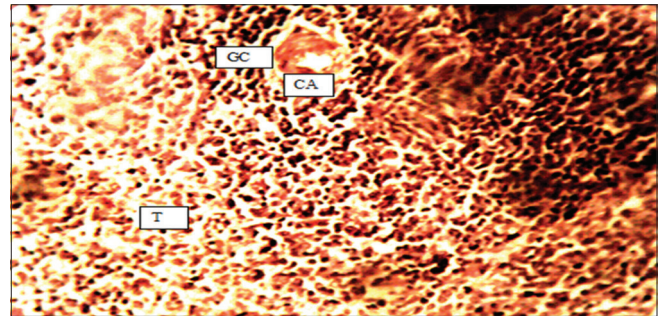
**Figure 1:** A cross-section of the spleen of the control group, showing normal histoarchitecture of white pulp, red pulp, trabeculae, and central artery (H and E, ×250)



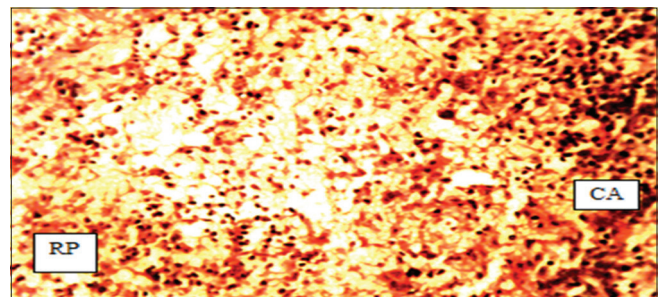
**Figure 3:** A cross-section of spleen of Group 3; showing narrowed trabeculae, severe central artery hemorrhage when compared to Group 2 (H and E, ×250)

## DISCUSSION

The toxicity of mercury has been shown to depend on the form and as such the various mercury compounds have different toxicities depending on their physical and chemical properties which affect absorption, distribution, tissue affinities, and stability within the bio-system (Aleo *et al.*, 2002). For instance, elemental mercury in the liquid state has unique toxic effects that differ from those of mercury vapor; likewise, organic mercury molecules are toxicologically different from inorganic forms (Levine *et al.*, 2000).  $HgCl_2$  is an inorganic compound used in various fields and its numerous effects were evaluated in many toxicity and carcinogenic studies because of its extensive use and wide occurrence as an environmental pollutant (Langford and Ferner, 1999; Levine *et al.*, 2000). Once absorbed,  $HgCl_2$  is distributed in all tissues and low fractions have been shown to easily cross the brain-blood barrier and the placenta (Jomova *et al.*, 2010).



**Figure 2:** A section of spleen of Group 2, showing ruptured central artery and vacuolization of germinal center with trabeculae necrosis (H and E, ×250)

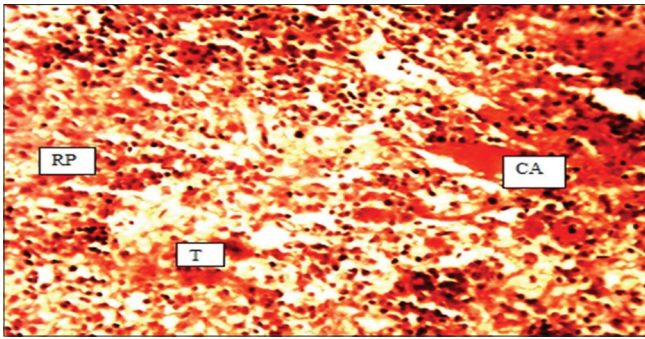


**Figure 4:** A transverse section of spleen of Group 4 showing sparsely packed cells, central artery (CA) not evident CA with normal red pulp (H and E, ×250)

**Table 2: Effect of ascorbic acid on mercury chloride-induced changes on the oxidative markers in experimental animals**

Groups	Mean±SEM			
	CAT (mm/ml)	SOD (m units/L)	GLU (mm/ml)	LPO (µM/L)
I Control	23.25±1.19	604.65±60.32	14.29±1.19	57.46±3.35
II 52.5 mg HgCl	12.52±5.30*	358.15±12.94*	10.04±1.16*	91.55±6.24*
III 26.25 mg HgCl	13.52±5.62*	382.75±24.39*	11.54±3.03*	70.39±6.59*
IV 52.5 mg/kg HgCl+Vitamin C	18.18±1.28*	472.75±77.15*	12.50±2.26*	52.82±14.79
V 26.25 mg/kg HgCl+Vitamin C	20.29±3.57	526.50±50.21	13.57±0.81	47.75±3.25*
VI Vitamin C 5 mg/kg	20.61±3.32	580.25±35.71	14.05±1.35	41.86±5.78*

\* $P < 0.05$ . CAT - Catalase, SOD - Superoxide dismutase, GLU - Glutathione reductase, LPO - Lipid-peroxidation, SEM - Standard error of the mean

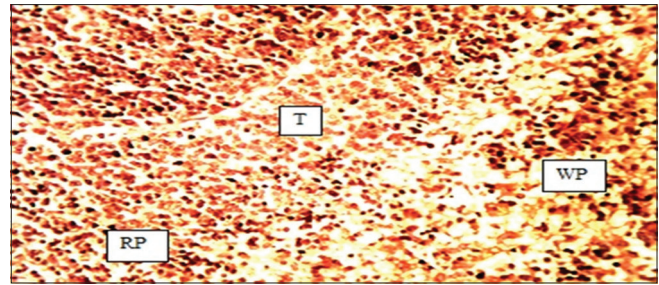


**Figure 5:** A section of spleen of Group 5 showing central artery hemorrhage with normal trabeculae and normal red pulp (H and E, ×250)

In the present study, histological examination has revealed that the spleen showed necrosis, hemorrhage and increased vacuolization of the cells and the severity was increased with increase in the concentration of the treatment (Bsoul and Terezhalmly, 2004; Glaser and Kiecolt-Glaser, 2005).

The result of hematological analysis showed there was a general decrease in the hematological parameters namely PCV, Hb and WBC in Groups treated with only mercury chloride which was in agreement with the result of Vahter *et al.*, (2000). The decrease revealed microcytic hypochromic anemia may be due to the effect of mercury chloride on activity of aminolevulinic acid dehydratase, the key enzyme of heme synthesis (Schurz *et al.*, 2000; Vahter *et al.*, 2000). Moreover mercury also inhibit the conversion of coproporphyrinogen III to protoporphyrin IX leading to reduction in Hb production and shortened life span of erythrocytes (Schurz *et al.*, 2000; Ruiz-Ramos *et al.*, 2010). This mechanism was proposed as one of the mechanism of lead induced oxidative damage by Vahter *et al.* (2000). Progressive destruction of RBCs due to the binding of mercury with RBCs, leading to increase fragility and destruction, could be another reason for the decrease in hematological indices (Grant and Lipman, 2009; Jomova and Valko, 2011). In the group that received both mercury chloride and Vitamin C, there was no increase in the PCV, Hb, WBC, and the value was slightly higher than that of the control group indicative of no spleen damage and hence ameliorative effect.

The present study revealed the ameliorative effects of ascorbic acid on the spleen of experimental animals induced with mercury chloride toxicity. Administration of ascorbic acid has some improvements in the prevention of the degeneration of splenic cells, infiltration, narrowing of lumen and hemorrhage in comparison with rats exposed to mercury chloride only (Jomova *et al.*, 2010). While from the observations in the present study, there was a direct relationship between the concentration of mercury chloride and the toxic effects on the spleen.



**Figure 6:** A section of the spleen of Group 6 showing normal cytoarchitecture of spleen with normal white pulp, red pulp, and normal trabeculae as compared to Group 1 (H and E, ×250)

## CONCLUSION

The present study has demonstrated that mercury chloride has effects on the weight of the body and the histology of the spleen of adult Wistar rats. Significant changes were also observed in biochemical parameters in the experimental Groups. Vitamin C has been shown to ameliorate the toxic effects of mercury chloride on the hematobiochemical parameters and has been shown to play important role in preventing oxidative damage to the spleen.

## REFERENCES

1. Aleo M.F, Morandini F, Bettoni F, Tanganelli S., Vezzola A., Giuliani R., *et al.* (2002). *In vitro* study of the nephrotoxic mechanism of mercuric chloride. *Med Lav* 93:267-78.
2. Badano M.N., Camicia G.L., Lombardi G., Maglioco A., Cabrera G., Costa H., *et al.* (2013). B-cell lymphopoiesis is regulated by cathepsin L. *PLoS One* 8 (4):e61347.
3. Bancroft J.D., Gamble M. (2008). *Theory and Practice of Histological Techniques* 6<sup>th</sup> ed. Churchill Livingstone Publishers, London. p. 70-71.
4. Brunet S., Guertin F, Flipo D., Fournier M., Krzystyniak K. (1993). Cytometric profiles of bone marrow and spleen lymphoid cells after mercury exposure in mice. *Int J Immunopharmacol* 15 (7):811-9.
5. Bsoul S.A., Terezhalmly G.T. (2004). Vitamin C in health and disease. *J Contemp Dent Pract* 5 (2):1-13.
6. Carr A.C., Frei B. (1999). Toward a new recommended dietary allowance for vitamin C based on antioxidant and health effects in humans. *Am J Clin Nutr* 69 (6):1086-107.
7. El-Shenawy S.M., Hassan N.S. (2008). Comparative evaluation of the protective effect of selenium and garlic against liver and kidney damage induced by mercury chloride in the rats. *Pharmacol Rep* 60 (2):199-208.
8. Ellman G.L. (1959). Tissue sulfhydryl groups. *Arch Biochem Biophys* 82 (1):70-2.
9. Vitamin C. (2007). Food Standards Agency, UK. wAvailable from: <http://www.food.gov.Uk/Vitamin.C>. [Last retrieved on 2012 Feb 20].
10. Fridovich I. (1989). Superoxide dismutases. An adaptation to a paramagnetic gas. *J Biol Chem* 264 (14):7761-4.
11. Ghosh A., Sil P.C. (2008). A protein from *Cajanus indicus* Spreng protects liver and kidney against mercuric chloride-induced oxidative stress. *Biol Pharm Bull* 31 (9):1651-8.
12. Glaser R., Kiecolt-Glaser J.K. (2005). Stress-induced immune dysfunction: Implications for health. *Nat Rev Immunol* 5 (3):243-51.
13. Grant L.D., Lipman M. (2009). *Environmental Toxicant: Human Exposure and Their Effect*. 3<sup>rd</sup> ed. Wiley Publishers, London, 108-12.



14. Higdon J. (2006). Vitamin C. Oregon State University, Micronutrient Information Center. Available from: <http://www.lpi.oregonstate.edu/infocenter/vitamins.html>. [Last retrieved on 2013 Mar 07].
15. Jomova K., Valko M. (2011). Advances in metal-induced oxidative stress and human disease. *Toxicology* 283 (2-3):65-87.
16. Jomova K., Vondrakova D., Lawson M., Valko M. (2010). Metals, oxidative stress and neurodegenerative disorders. *Mol Cell Biochem* 345 (1-2):91-104.
17. Kurl S., Tuomainen T.P., Laukkanen J.A., Nyyssönen K., Lakka T., Sivenius J., et al. (2002). Plasma vitamin C modifies the association between hypertension and risk of stroke. *Stroke* 33 (6):1568-73.
18. Langford N., Ferner R. (1999). Toxicity of mercury. *J Hum Hypertens* 13 (10):651-6.
19. Levine M., Rumsey S.C., Wang Y., Park J.B., Daruwala R. (2000). Vitamin C. In: Stipanuk M.H., editor. *Biochemical and Physiological Aspects of Human Nutrition*. W.B. Saunders, Philadelphia, 541-67.
20. Lucky T.D. (1987). *Metal Toxicity in Mammals*. Vol. 2. Plenum Press, New York, 182.
21. Magos L., Clarkson T.W. (2006). Overview of the clinical toxicity of mercury. *Ann Clin Biochem* 43 (Pt 4):257-68.
22. Niehaus W.G., Samuelson B. (1968). Formation of malnaldehyde from phospholipid arachidonate during microsomal lipid peroxidation. *Eur Biochem* 6 (1):126-30.
23. Padayatty S.J., Katz A., Wang Y., Eck P., Kwon O., Lee J.H., et al. (2003). Vitamin C as an antioxidant: Evaluation of its role in disease prevention. *J Am Coll Nutr* 22 (1):18-35.
24. Pathak S.K., Bhowmik M.K. (1998). The chronic toxicity of inorganic mercury in goats: Clinical signs, toxicopathological changes and residual concentrations. *Vet Res Commun* 22 (2):131-8.
25. Rajagopalan H., Jallepalli P.V., Rago C., Veleulescu V.E., Kinzler K.W., Vogelstein B., et al. (2004). Inactivation of hCDC4 can cause chromosomal instability. *Nature* 428 (6978):77-81.
26. Risher J.F., Amler S.N. (2005). Mercury exposure: Evaluation and intervention the inappropriate use of chelating agents in the diagnosis and treatment of putative mercury poisoning. *Neurotoxicology* 26 (4):691-9.
27. Ruiz-Ramos M., Vargas L.A., Fortoul Van der Goes T.I., Cervantes-Sandoval A., Mendoza-Nunez V.M. (2010). Supplementation of ascorbic acid and alpha-tocopherol is useful to preventing bone loss linked to oxidative stress in elderly. *J Nutr Health Aging* 14 (6):467-72.
28. Schurz F., Sabater-Vilar M., Fink-Gremmels J. (2000). Mutagenicity of mercury chloride and mechanisms of cellular defence: The role of metal-binding proteins. *Mutagenesis* 15 (6):525-30.
29. Senese F. (2007). Why is mercury a liquid at STP? General Chemistry Online at Frostburg State University. Available from: [http://www.antoine.frostburg.edu/chem/Senese/101/inorganic/faq/why\\_is\\_mercury\\_liquid.shtml](http://www.antoine.frostburg.edu/chem/Senese/101/inorganic/faq/why_is_mercury_liquid.shtml). [Last retrieved on 2014 May 01].
30. Sinha A.K. (1972). Colorimetric assay of catalase. *Anal Biochem* 47 (2):389-94.
31. Son H.Y., Lee S., Park S.B., Kim M.S., Choi E.J., Singh T.S., et al. (2010). Toxic effects of mercuric sulfide on immune organs in mice. *Immunopharmacol Immunotoxicol* 32 (2):277-83.
32. Vahter M., Akesson A., Lind B., Björs U., Schütz A., Berglund M. (2000). Longitudinal study of methylmercury and inorganic mercury in blood and urine of pregnant and lactating women, as well as in umbilical cord blood. *Environ Res* 84 (2):186-94.
33. Verma S., Waldschmidt T.J. (2007). Characterization of splenic CD21hi T2 B cells. *Immunol Res* 39 (1-3):240-8.
34. World Health Organization. (2004). *Vitamin and Mineral Requirements in Human Nutrition*. 2<sup>nd</sup> ed. World Health Organization, Geneva; Switzerland, 1-341.

**How to cite this article:** Ibegbu AO, Micheal A, Abdulrazaq AA, Daniel B, Sadeeq AA, Peter A, Hamman WO, Umana UE, Musa SA. Ameliorative effect of ascorbic acid on mercury chloride-induced changes on the spleen of adult wistar rats. *J Exp Clin Anat* 2014;13:60-5.

**Source of Support:** Nil, **Conflict of Interest:** None declared.