



Effects of *Vernonia ambigua* on testicular histology, selected semen profiles and serum oxidative stress biomarkers of Wistar rats

¹Igwe, E.C.; ²Besong, E.E.; ³Esomchi, C.N.; ³Nwofia, J.O.; ¹Okoche, M.C.; ¹Onigbo, E.O.

Abstract

BACKGROUND AND AIM: Infertility has become an ever-present growing reproductive concern worldwide, with male factors evading required scrutiny due to entrenched cultural beliefs, in lieu of scientific proofs. Though researchers' contribution is palpable, there is still persistent need for more study in this area. This study aimed to evaluate the effects of *Vernonia ambigua* on testicular histology, selected semen profiles and serum oxidative stress biomarkers of Wistar rats

METHODOLOGY: Twenty rats weighing 200-220g were grouped into four. Each group had five rats. Group A received feed and water. Groups B, C and D received 100mg/kg body weight, 200 mg/kg body weight and 400 mg/kg body weight of *Vernonia ambigua* respectively for 2 weeks. On the 15th day, blood (serum) samples were collected for oxidative stress biomarkers estimation. Histology of the testis and semen parameters were examined. One way Analysis of Variance in Statistical Package for Social Science was used for data analysis with significance difference set at $P < 0.05$.

RESULTS: Mild testicular distortion was observed in group D. The levels of glutathione, catalase, superoxide dismutase and malondialdehyde in groups B, C and D showed no significant difference when compared to levels of the variables in group A. The same outcome was observed in the comparison of sperm viability, morphology and count of groups B, C and D to group A.

CONCLUSION: *Vernonia ambigua* at lower dose, shows promising antioxidant and reproductive effects especially when sperm viability is preferred to sperm count.

Keywords:

Vernonia ambigua, testis, semen profiles

Submitted: 25th November, 2024

Revised: 10th December, 2024

Accepted: 12th December, 2024

Published: 31st December, 2024

¹Department of Anatomy, Faculty of Basic Medical Sciences, College of Health Sciences, Ebonyi State University, P. M. B. 053, Abakaliki, Ebonyi State, Nigeria; ²Department of Physiology, Faculty of Basic Medical Sciences, College of Health Sciences, Ebonyi State University, P. M. B. 053, Abakaliki, Ebonyi State, Nigeria; ³Department of Anatomy, Faculty of Basic Medical Sciences, College of Medicine, Alex Ekwueme Federal University, P. M. B. 1010, Ikwo, Ebonyi State, Nigeria.

Address for Correspondence:

Igwe, E.C.

Department of Anatomy, Faculty of Basic Medical Sciences, College of Health Sciences, Ebonyi State University, Abakaliki, Ebonyi State, Nigeria.

igwece@gmail.com

INTRODUCTION

Accumulating evidence indicates increasing prevalence of human infertility over the past decades (Ayad *et al.*, 2022). Infertility, one of the most complex disorders of the reproductive system, is defined as the inability to conceive after one year or more of regular unprotected sexual intercourse (Barrera *et al.*, 2022). Globally, infertility affects approximately 15% of couples of reproductive ages (Assidi, 2022). Studies indicate that male factors alone account for approximately 20–30% of infertility cases and roughly half of all infertility cases are attributed to male factors (Diaz *et al.*, 2022). Despite significant advancements in the diagnosis and treatment of male infertility, nearly half of these cases remain idiopathic, meaning

no clear etiological factor can be identified (Ghuman and Ramalingam, 2018).

In recent years, concerns have been raised about the increasing rates of male infertility, reflecting aglobal decline in semen quality and a rise in male reproductive abnormalities (Famurewa *et al.*, 2023; Okafor *et al.*, 2021; Irozuoke *et al.*, 2024). Although the particular reason for the increased incidence of male infertility remains elusive, various environmental, nutritional and socioeconomic factors have been suggested to contribute to the downward trend in semen quality (Skoracka *et al.*, 2020; Balawender and Orkisz, 2020). Furthermore, common complications including obesity, dyslipidaemia,

This is an open access journal, and articles are distributed under the terms of the Creative Commons Attribution-Non Commercial-Share Alike 4.0 License, which allows others to remix, tweak, and build upon the work non-commercially, as long as appropriate credit is given and the new creations are licensed under the identical terms.

For reprints contact: jecajournal@gmail.com

How to cite this article: Igwe, E.C.; Besong, E.E.; Esomchi, C.N.; Nwofia, J.O.; Okoche, M.C.; Onigbo, E.O. Effects of *Vernonia ambigua* on testicular histology, selected semen profiles and serum oxidative stress biomarkers of Wistar rats. *J Exp Clin Anat* 2024; 21(2): 385-392.

<https://dx.doi.org/10.4314/jeca.v21i2.33>

hypertension, insulin resistance as well as psychological stress and anxiety have also been associated with impaired fertility in males of reproductive potential (Leisegang and Dutt, 2021; Esomchi *et al.*, 2023). The link between these comorbidities and male infertility appears to be complicated and poorly understood. However, there is research-based evidence demonstrating that oxidative damage is one of the fundamental mechanisms involved in the etiopathogenesis of these illnesses (Ojo *et al.*, 2023). Concurrently, the critical role of oxidative stress (OS) in the development of male reproductive dysfunction has continued to gain a great deal of attention (Martin-Hidalgo *et al.*, 2019; Martins da Silva and Anderson, 2022).

Reactive oxygen species (ROS) at physiological levels are essential for male fertility, particularly in processes like acrosome reaction and capacitation. However, spermatozoa, with their limited antioxidant capacity and cell membranes rich in polyunsaturated fatty acids (PUFAs), are highly susceptible to oxidative damage (Khoploiklang *et al.*, 2024). Under certain pathological conditions, ROS can be converted into highly reactive agents, causing dysregulation of various cellular signalling pathways and extensive damage to multiple biomolecules including nucleic acids, proteins, and lipids. The subsequent series of adverse events include loss of membrane integrity, mitochondrial dysfunction, impaired sperm motility as well as DNA damage and apoptosis (Akhigbe *et al.*, 2024; Ritchie and Ko, 2021). To mitigate the effects of elevated ROS, various therapeutic approaches have explored both synthetic and natural antioxidants (Ovie *et al.*, 2023). Examples of these natural antioxidants include *Citrus aurantifolia* (Akunna *et al.*, 2020), *Cucumeropsis mannii* (Agu *et al.*, 2022), *Cocos nucifera* (Nwafor *et al.*, 2021), *Loranthus micranthus* (Ebokaiwe *et al.*, 2018), *Syzygium aromaticum* (Uchewa *et al.*, 2023), *Vernonia amygdalina* (Nweke *et al.*, 2022) and a host of others have shown promise in reducing oxidative damage.

On the other hand, *Vernonia ambigua* has been reported to be consumed in various parts of the world and used to treat various ailments (Aliyu *et al.*, 2015). Nonetheless, its effects on different parameters especially on fertility enhancement and oxidative stress remain poor, hence, the need for this study.

MATERIALS AND METHODS

Plants Collection and Identification and Extraction

A sample of the fresh plants of *V. ambigua* with their flowers and roots intact was collected locally from Ochudo City, Abakaliki Local Government Area, Ebonyi State, Nigeria for identification – a process that was conducted by a taxonomist in the Applied Biology Department of Ebonyi State University. The voucher (herbarium) number assigned to the plant was EBSU-H-1100. A large portion of the plants was obtained after the identification. This is followed by the defoliation as well as drying of the leaves

at room temperature. The dried leaves were carefully grinded into a powder and weighed (190g) and subsequently stored in an air tight container.

Absolute alcohol manufactured by Gungdong Guandgua Chemical Factory Co. Ltd {CAS(7778-80-5)M.P.1069*cB.P.1689*D2.66; Lot number 20100408} was mixed with the powdered leaves in the ratio of 1:5 (1 gramme of *V. ambigua* with 5 ml of the absolute alcohol) in an air-tight container. The mixture was stirred every 6 hours, left tightly covered with lid of the container and kept in a room temperature for 3 days. After the 3 days, double folded sieve cloth with fine pores and two Whatman filter paper No 1 were used for the filtration of the mixture with the former being the first and the later serving in the second filtration procedure. To concentrate the resultant ethanol containing filtrate, the filtrate was placed in water bath set at a temperature of 40°C to facilitate the evaporation of the ethanol. A sticky texture of the extract was obtained. An electronic weighing balance was used to determine the weight of the army colour sticky ethanol extract of *V. ambigua* which weighed 21.6 g. Stock solution of the extract for this study was constituted in accordance with the procedure stated in the Organisation of Economic Cooperation and Development (OECD) adopted in 16th October 2008 and Corrected in 30th June 2022 (OECD, 2022) and refrigerated to maintain its efficacy.

Ethical Consideration

This study followed the stipulated guideline provided in Guide for the Care and Use of Experimental Animals-Eighth Edition (National Research Council, 2011) which was approved by the Faculty of Basic Medical Sciences (FBMS) Research and Ethics Committee of Ebonyi State University, Abakaliki, Ebonyi State, Nigeria with an ethical approval number (EBSU/FBMS/REC/2019/08/009) assigned.

Experimental Procedure

Twenty (20) male rats with a weight range of 200-220g were procured from the Animal Research Facility of the FBMS, Ebonyi State University. The animals were kept in a well-ventilated cage and left to acclimatize for two (2) weeks at room temperature (12:12h light/dark cycle) with free access to feed and water.

Prior to the inception for the administration of extract, the animals were grouped into A, B, C and D each containing five (5) male Wistar rats. Groups A continued to received feed and water. In addition to receiving feed and water, groups B, C and D were administered 100mg/kg body weight, 200mg/kg body weight and 400mg/kg body weight of *V. ambigua* respectively once daily for fourteen (14) days with the aid of orogastric tube connected to the end of a 2ml syringe. The choice of the dosage in this study was based on the reported lethal dose of more than 5000 mg/kg body weight of *V. ambigua* which was authenticated by Builders *et al.*, (2011). On day 15, the animals in all the groups were

sacrificed by cervical dislocation and the testes were removed and fixed in 10% formol saline for routine histological procedure. Blood samples were also extracted from by ocular puncture for laboratory estimation of the oxidative stress biomarkers. For the semen analysis, the epididymal sperm preparation and sperm count was based the method used by Yokoi and Mayi (2004) while motility and sperm morphology were conducted following World Health Organisation, (1999) and Perreault and Cancel (2001) procedures respectively. Sperm viability was obtained by the summation of progressively motile sperms and sluggishly motile sperms which were all expressed in percentages (%).

Procedures for Determination of the Selected Oxidative Stress Biomarkers

Reduced glutathione (GSH) was measured based on the procedure of Beutler et al. (1963). Superoxide dismutase was measured in compliance with the method of Nishikimi et al. (1972). In the estimation of Catalase and malondialdehyde the methods of Aebi (1984) and Gutteridge JM, Wilkins (1982) were adopted respectively.

Data Analysis

The data obtained from this study was entered into International Business Machine Statistical Package for Social Science (IBMSPSS) version 25. One way Analysis of Variance in the IBMSPSS was used for the analysis. The results were presented as mean ± Standard Error of Mean (SEM). Further comparison of each of the three groups (B, C and D) in this study to the control group (group A) was conducted using *Tukey Post Hoc Test*. The significance level was set at $P < 0.05$.

RESULTS

Effects of *Vernonia ambigua* on Serum Oxidative Stress Biomarkers

Table 1 shows the mean values of Glutathione (GSH), Malonaldehyde (MDA), Superoxide Dismutase (SOD), and Catalase (CAT) across Group A and experimental groups B, C, and D. GSH levels though higher in groups B (78.08±7.80), C (92.83±21.04) and D (92.14±23.94) were not significantly difference when compared to GSH levels in Group A (59.18±8.75). The lower MDA levels in B (1.14±0.16), C (1.25±0.12) and D (1.40±0.12) showed no significant difference when compared to MDA levels in Group A (1.60±0.16). The levels of SOD in groups A, B, C and D showed almost similar mean values across groups with the comparison of the SOD level in groups B (11.20±0.02), C (11.17±0.0), and D (10.65±0.53) to group A showing no significant difference. However, CAT depicted no significant difference in the comparison of its higher levels observed in B (8.51±2.72), C (6.12±2.97), and D (6.46±0.39) to Group A (3.78±1.71).

Effects of *V. ambigua* on Semen Analysis

Table 2 shows the mean values of sperm viability, morphological anomaly, and sperm count of the Wistar rats in groups B, C, D and A. The results from table 2 further indicated no significant difference in the sperm viability when groups B (77.50±4.33), C (63.75±7.18), and D (70.00±4.08) was compared to Group A (75.00±2.89). The comparison of morphological anomaly of sperm in groups B (17.75±2.02), C (15.25±1.75), and D (14.75±2.17) to Group A (10.25±0.85) showed no significant difference as well the comparison of sperm counts in groups B (31.25±3.79), C (43.50±6.20), and D (37.00±7.01) to Group A (36.00±1.96).

Histopathological Evaluation of Testes Following Administration of *V. ambigua*

Group A presented normal testicular structure of seminiferous tubules (ST) within which are found spermatogonia (SG), clustering spermatozoa (CSZ) in the lumen of the ST, germinal epithelium (GE) containing the sustentacular cells or Sertoli cells (SC) and developing spermatocytes. Photomicrograph of the section of the testis from group B also showed CSZ within the lumen of the ST. Normal morphology of the SG and inherent intact nature of the germinal epithelium (GE) {with its SC and developing spermatocytes} were observed. In group C, increased number of spermatogonia cells within the basal compartment (parts of the ST below the connecting junctions between two adjacent SCs) of ST and GE were observed in addition to mild loss of compactness of the components of GE. Furthermore, group D also showed a photomicrograph displaying presence of mild distortion of inherent intact appearance of the GE (DIGE).

Table 1: Showing Mean Values of Serum Oxidative Biomarkers

Groups	GSH (mg/dl)		MDA (mg/dl)	
	Mean ± SEM	P-values	Mean ± SEM	P-values
A	59.18±8.75		1.60±0.16	
B	78.08±7.80	0.83	1.14±0.16	0.14
C	92.83±21.04	0.46	1.25±0.12	0.33
D	92.14±23.94	0.48	1.40±0.12	0.74
Groups	SOD (U/mg)		CAT (U/mg)	
	Mean ± SEM	P-values	Mean ± SEM	P-values
A	11.19±0.01		3.78±1.71	
B	11.20±0.02	1.00	8.51±2.72	0.42
C	11.17±0.01	1.00	6.12±2.97	0.86
D	10.65±0.53	0.42	6.46±0.39	0.81

Table 2: Showing the Effects of *V. ambigua* on Selected Semen Parameters

Groups	Viability (%)		Morphological anomaly		Sperm count (x 10 ⁶ /ml)	
	Mean ±SEM	P-values	Mean ±SEM	P-values	Mean ±SEM	P-values
A	75.00±2.89		10.25±0.85		36.00±1.96	
B	77.50±4.33	0.98	17.75±2.02	0.05	31.25±3.79	0.91
C	63.75±7.18	0.40	15.25±1.75	0.24	43.50±6.20	0.74
D	70.00±4.08	0.89	14.75±2.17	0.32	37.00±7.01	1.00

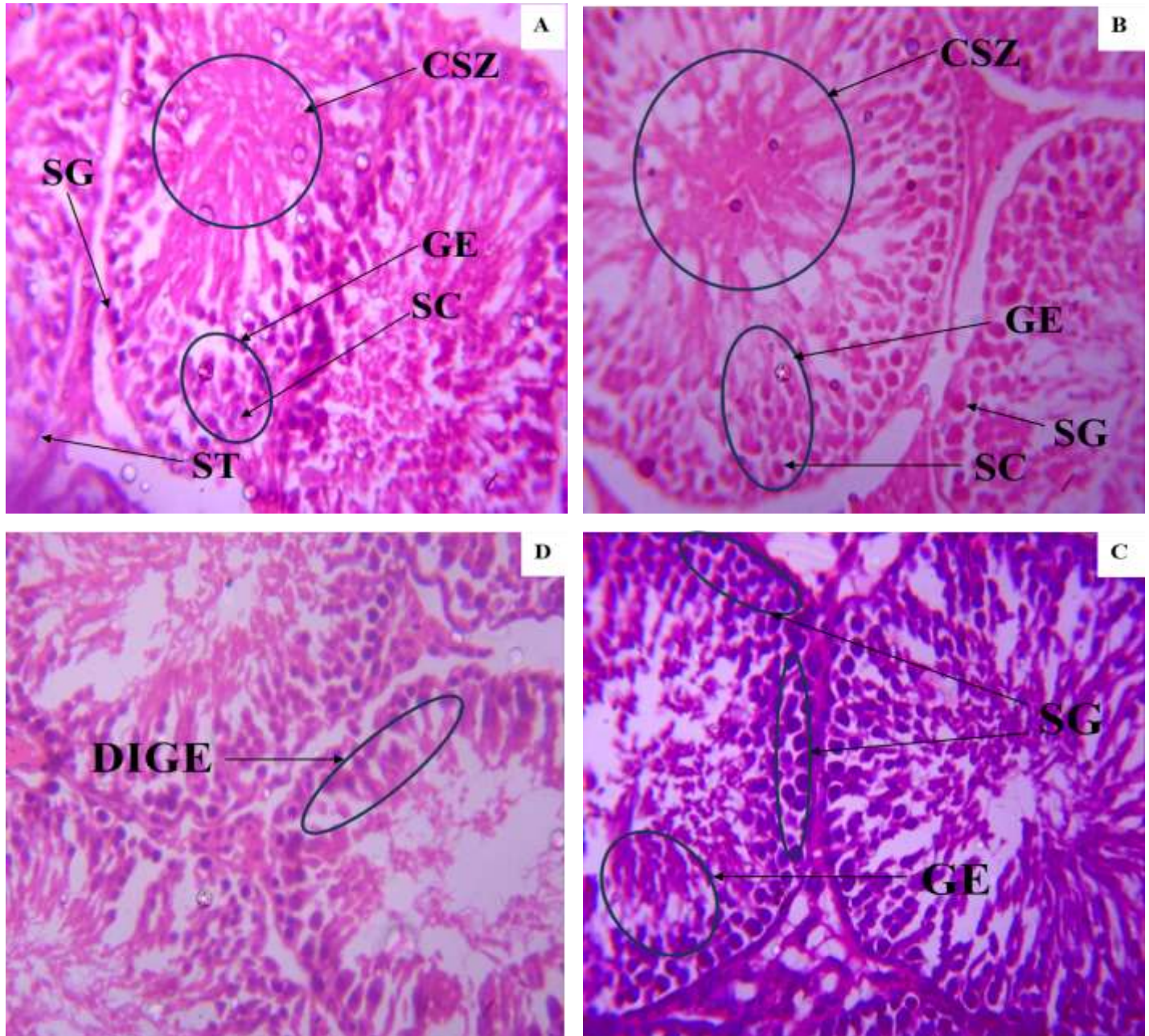


Figure 1: Indicates the photomicrograph of the sections of testis from Groups A, B, C and D. Groups A received feed and water while Groups B, C and D received 100 mg/kg body weight, 200 mg/kg body weight and 400 mg/kg body weight of *V. ambigua* respectively. ST, SG, CSZ, GE, SC and DIGE denotes seminiferous tubules, spermatogonia, clustering spermatozoa, germinal epithelium, sustentacular cells or Sertoli cells and distortion of inherent intact appearance of the GE respectively. {Haematoxylin and Eosin (H&E); x 400}.

DISCUSSION

Medicinal plants have been used to prevent and treat various health problems for many ages (Nowak *et al.*, 2022). Consequently, there has been a growing interest in exploring natural products for the prevention and treatment of infertility (Noh *et al.*, 2020). Furthermore, the prevalence of infertility in both developing and developed countries has prompted research into alternative approaches to address fertility issues (Salhi *et al.*, 2024). Within this framework, natural products such as *V. ambigua* have garnered attention as potential interventions, but there is paucity on the role(s) of *V. ambigua* in male fertility. In this current study, the effects of *V. ambigua* on selected reproductive indices and oxidative stress parameters of male Wistar rats were examined.

Oxidative stress is one of the major causes of defective generative function (García-Sánchez *et al.*, 2020). Oxidative stress arises from an imbalance between ROS and protective antioxidants and influences the entire reproductive lifespan of men and women (Adeoye *et al.*, 2018). Elevated levels of ROS directly damage sperm DNA and induce apoptosis in sperm (Alturki *et al.*, 2022). In the male reproductive system, ROS disrupts the integrity of the sperm DNA and contributes to lipid peroxidation (Ojo *et al.*, 2023). Our findings indicate that *V. ambigua* has mixed effects on semen profiles.

Sperm viability increased at 100 mg/kg body weight of the extract but decreased at 200 mg/kg body weight and 400 mg/kg body weight of *V. ambigua*, though it was of no significant difference when compared to the control group (table 2). This finding seems to agree to the safety of *V. ambigua* reported by Builders *et al.*, (2011) when they stated the lethal dose of the plant under study to be more than 5000 mg/kg of body weight. Sperm morphology examined in this study statistically in the test groups (B, C and D) shared the same morphological anomaly as the control group which further reinforces the view that crude ethanol leaf extract of *V. ambigua* has a high safety score as stated by Builders *et al.*, (2011). These findings also align with previous studies reporting mixed effects of medicinal plants on semen parameters (Nejabatbakhsh *et al.*, 2016; Boroujeni *et al.*, 2022). Though the reported morphological anomaly detected following administrations of *V. ambigua* was of no significant difference when compared to control group, it is vital to state, particularly in rural communities where plants like *V. ambigua* and related species are commonly consumed (Aliyu *et al.*, 2011), that such anomaly maybe due to the presence of phytoestrogens in *V. ambigua*. These phytoestrogens which are natural compounds are known to disrupt reproductive function (Canivenc-Lavier and Bennetau-Pelissero, 2023). Previous studies have reported that phytoestrogens could be toxic to different organs of the body (Wanibuchi *et al.*, 2003; Rietjens *et al.*, 2017; Khushboo *et al.*, 2023) such as the reproductive system thereby reducing fertility (Csupor-Löffler *et al.*, 2009) though such toxicity was not observed

in the findings of this study. It could also be possible the geographical location and time of leaf collection as well as the procedure of its extraction hinders or drastically reduce the toxicity of the phytoestrogens.

Moreover, oxidative stress plays a key role in impaired reproductive function. An increase in oxidative stress and a reduction in antioxidants are often associated with poor semen quality (Sengupta *et al.*, 2024). In our study, oxidative stress levels decreased across the groups as the dose of *V. ambigua* increased, while antioxidant levels improved. The extract enhanced the activity of key antioxidant enzymes, such as catalase (CAT), superoxide dismutase (SOD), and glutathione (GSH), which are crucial in neutralizing ROS and lower lipid peroxidation as shown in the lower levels of malondialdehyde (MDA). These findings are consistent with previous reports which suggested that medicinal plants can mitigate oxidative stress and boost antioxidant defense mechanisms (Uchewa *et al.*, 2020; Akunna *et al.*, 2023; Agbor *et al.*, 2023).

The antioxidant properties of *V. ambigua* are likely linked to its phytochemical constituents, which have been identified as natural antioxidants. This reduction in oxidative stress was evident in the photomicrographs, which showed mild distortions in the testicular histoarchitecture in group C and D. Furthermore, the observed increase in the number of SGs in group C may be among the reasons accounting for the upward spike in sperm count but was not translated into spermatozoa viability (table 2 and photomicrograph C). This finding (table 2) seems to suggest that if presence of millions of sperms in an ejaculate is to ensure fertilization, then preferring viability to increase in sperm count with less viability is not out place. These results align with other studies that have demonstrated improvements in histology when using medicinal plants, though certain measured parameters may still be negatively impacted (Orieke *et al.*, 2019).

Conclusion: Generally, this study demonstrates that *V. ambigua* exhibits dose-dependent effects on the considered male reproductive indices and oxidative stress biomarkers in Wistar rats. Specifically, lower dose of *V. ambigua* seems preferable when sperm viability is concluded as a criterion for conception instead of sperm count and for improved testicular histology. The antioxidant properties of *V. ambigua* highlight its potential to reduce oxidative stress, though careful consideration of dosage is crucial to ensure safety.

Data Availability Statement: The data that support the findings of this study are available from the corresponding author upon request.

Funding Statement: This research received no specific grant from any funding agency in the public, commercial, or non-profit sectors.

Conflict of Interest Disclosure: The authors declare that they have no conflict of interest.

REFERENCES

- Adeoye O, Olawumi J, Opeyemi A, Christiania O. (2018). Review on the role of glutathione on oxidative stress and infertility. *JBRA Assist Reprod.* 22(1):61–66.
- Aebi H. (1984). Catalase in vitro. *Methods Enzymol.* 105:121-126.
- Agbor GA, Kuiaté JR, Sangiovanni E, Ojo OO. (2023). Editorial: The role of medicinal plants and natural products in modulating oxidative stress and inflammatory related disorders, Volume II. *Front Pharmacol* 14:1310291
- Agu PC, Aja PM, Ekpono UE, Ogwoni HA, Ezeh EM, Oscar-Amobi PC, et al. (2022) Cucumeropsis mannii seed oil (CMSO) attenuates alterations in testicular biochemistry and histology against Bisphenol a-induced toxicity in male Wister albino rats. *Heliyon.* 8(3): e09162.
- Akhigbe RE, Akhigbe TM, Oyedokun PA, Famurewa AC. (2024). Molecular mechanisms underpinning the protection against antiretroviral drug-induced sperm-endocrine aberrations and testicular toxicity: A review. *Reprod Toxicol.* 128:108629.
- Akunna G, Ihechu P, Ajeleti A, Olabisi O, Famurewa A, Enye L. (2020). Aqueous peel extract of *Citrus aurantifolia* attenuated tramadol-mediated testicular oxidative stress, apoptosis, inflammations and histo-architectural degeneration in a rat model. *Eur J Anat.* 24(5): 429–437.
- Akunna GG, Freitas A, Keikwe V, Lucyann CA, Saalu LC. (2023). Economic Importance of *Garcinia Kola*: Evidences of Shielding Outcome Against Carbon Tetrachloride-Induced Kidney Toxicity in Experimental Models. *J Innov Med Res.* 2(10):64–72.
- Aliyu AB, Musa AM, Abdullahi MS, Ibrahim H, Oyewale AO. (2011). Phytochemical screening and antibacterial activities of *Vernonia ambigua*, *Vernonia blumeoides* and *Vernonia oocephala* (Asteraceae). *Acta Pol Pharm.* 68(1):67–73.
- Aliyu AB, Oshanimi JA, Sulaiman MM, Gwarzo US, Garba ZN, Oyewale AO. (2015). Mineral element profiles of *Vernonia ambigua*, *Vernonia oocephala* and *Vernonia pupurea* used in Northern Nigerian traditional medicine. *Vitae.* 22(1):27–32.
- Alturki HA, Elsayy HA, Famurewa AC. (2022). Silymarin abrogates acrylamide-induced oxidative stress-mediated testicular toxicity via modulation of antioxidant mechanism, DNA damage, endocrine deficit and sperm quality in rats. *Andrologia.* 54(9): e14491.
- Assidi M. (2022). Infertility in Men: Advances towards a Comprehensive and Integrative Strategy for Precision Theranostics. *Cells.* 11(10):1711.
- Ayad B, Omolaoye TS, Louw N, Ramsunder Y, Skosana BT, Oyeipo PI, et al. (2022). Oxidative Stress and Male Infertility: Evidence from a Research Perspective. *Front Reprod Health.* 4:822257.
- Balawender K, Orkisz S. (2020). The impact of selected modifiable lifestyle factors on male fertility in the modern world. *Cent European J Urol.* 73(4):563–568.
- Barrera N, Omolaoye TS, Du Plessis SS. (2022). Chapter 6 - A contemporary view on global fertility, infertility, and assisted reproductive techniques. In: Vaamonde D, Hackney AC, Garcia-Manso JM, editors. *Fertility, Pregnancy and Wellness.* Elsevier; p. 93–120.
- Beutler E, Duron O, Kelly BM. (1963). Improved method for the determination of blood glutathione. *J Lab Clin Med.* 61:882-888.
- Boroujeni SN, Malamiri FA, Bossaghzadeh F, Esmaeili A, Moudi E. (2022). The most important medicinal plants affecting sperm and testosterone production: a systematic review. *JBRA Assist Reprod.* 26(3):522–530.
- Builders MI, Wannang NN, Ajoku GA, Builders PF, Orisadipe A, Aguiyi JC. (2011). Evaluation of the Antimalarial Potential of *Vernonia ambigua* Kotschy and Peyr (Asteraceae). *Int. J. Pharmacol.* 7: 238-247.
- Canivenc-Lavier MC, Bennetau-Pelissero C. (2023). Phytoestrogens and Health Effects. *Nutrients.* 15(2):317.
- Csupor-Löffler B, Hajdú Z, Zupkó I, Réthy B, Falkay G, Forgo P, et al. (2009). Antiproliferative effect of flavonoids and sesquiterpenoids from *Achillea millefolium* s.l. on cultured human tumour cell lines. *Phytother Res.* 23(5):672–676.
- Diaz P, Dullea A, Chu KY, Zizzo J, Loloi J, Reddy R, et al. (2022). Future of Male Infertility Evaluation and Treatment: Brief Review of Emerging Technology. *Urology.* 169:9–16.
- Ebokaiwe AP, Ijomone OM, Osawe SO, Chukwu CJ, Ejike CECC, Zhang G, et al. (2018). Alteration in sperm characteristics, endocrine balance and redox status in rats rendered diabetic by streptozotocin treatment: attenuating role of *Loranthus micranthus*. *Redox Rep.* 23(1):194–205.
- Esomchi CN, Ishicheli GK, Nnaka J, Nwofia JO, (2023). Chukwu MA. Prevalence of obesity by occupation among male residents of South East Nigeria. *J Anat Sci.* 14(2):91–96.
- Famurewa AC, Hamdi H, Sedky A. (2023). Lipoic acid abates testis lead accumulation, sperm endocrine deficits, testicular oxidative inflammation and apoptosis and modulates gene expression of Bax and Bcl-2 in rats. *Sci African.* 21: e01842.
- García-Sánchez A, Miranda-Díaz AG, Cardona-Muñoz EG. (2020) The Role of Oxidative Stress in Physiopathology and Pharmacological Treatment with Pro- and Antioxidant

- Properties in Chronic Diseases. *Oxid Med Cell Longev*. 2020:2082145.
- Ghuman N, Ramalingam M. Male infertility. (2018). *Obstet Gynaecol Reprod Med*. 28(1):7–14.
- Gutteridge JM, Wilkins S. (1982). Copper-dependent hydroxyl radical damage to ascorbic acid: formation of a thiobarbituric acid-reactive product. *FEBS Lett*. 137(2):327-330.
- Irozuoke AC, Akunna GG, Saalu LC. (2024). Modulating Effects of Clove Isolates on Testicular Pathohistological, Sperm-redox Status of Trichloroacetic Acid-Treated Rats. *Int J Heal Pharm Res*. 9(3):14–38.
- Khophloiklang V, Chanapiwat P, Kaeoket K. (2024). Camellia oil with its rich in fatty acids enhances post-thawed boar sperm quality. *Acta Vet Scand*. 66(1):6.
- Khushboo M, Sanjeev S, Murthy MK, Sunitadevi M, Dinata R, Bhanushree B, et al. (2023). Dietary phytoestrogen diosgenin interrupts metabolism, physiology, and reproduction of Swiss albino mice: Possible mode of action as an emerging environmental contaminant, endocrine disruptor and reproductive toxicant. *Food Chem Toxicol*. 2023; 176:113798.
- Leisegang K, Dutta S. (2021). Do lifestyle practices impede male fertility? *Andrologia*. 53(1): e13595.
- Martin-Hidalgo D, Bragado MJ, Batista AR, Oliveira PF, Alves MG. (2019). Antioxidants and Male Fertility: from Molecular Studies to Clinical Evidence. *Antioxidants (Basel, Switzerland)*. 8(4):89.
- Martins da Silva S, Anderson RA. (2022). Reproductive axis ageing and fertility in men. *Rev Endocr Metab Disord*. 23(6):1109–1121.
- National Research Council (US) (2011). National Academics Press. Guide for the Care and Use of Laboratory Animals. 8th ed. US; Washington DC. Available from: <http://grants.nih.gov/grants/olaw/guide-for-the-care-and-use-of-laboratory-animals.pdf>
- Nejatbakhsh F, Shirbeigi L, Rahimi R, Abolhassani H. (2016). Review of local herbal compounds found in the Iranian traditional medicine known to optimise male fertility. *Andrologia*. 48(8):850–859.
- Nishikimi M, Appaji N, Yagi K. (1972). The occurrence of superoxide anion in the reaction of reduced phenazine methosulfate and molecular oxygen. *Biochem Biophys Res Commun*. 46(2):849-54.
- Noh S, Go A, Kim D Bin, Park M, Jeon HW, Kim B. (2020). Role of Antioxidant Natural Products in Management of Infertility: A Review of Their Medicinal Potential. *Antioxidants (Basel, Switzerland)*. 9(10):957.
- Nowak J, Kiss AK, Wambebe C, Katuura E, Kuźma Ł. (2022). Phytochemical Analysis of Polyphenols in Leaf Extract from *Vernonia amygdalina* Delile Plant Growing in Uganda. *Appl Sci*. 12(2):912.
- Nwafor JA, Uduma-Ukpai C, Okechukwu J, Uchewa O, Ekaikite O, Ikpeze S. (2021). Biotherapeutic sufficiency of virgin coconut oil on paraquat-mediated reproductive dysfunction. *J Anat Soc India*. 70(2):106–112.
- Nweke EO, Ofoegbu CC, Elendu MU, Ugboaja CI, Eziama OD. (2022). Evaluation of the effect of ethanol leaf extract of *Vernonia amygdalina* on the Testicle of Diabetic Wistar Rats. *GSC Biol Pharm Sci*. 20(2):220–225.
- Ojo OA, Nwafor-Ezeh PI, Rotimi DE, Iyobhebhe M, Ogunlakin AD, Ojo AB. (2023). Apoptosis, inflammation, and oxidative stress in infertility: A mini review. *Toxicol Rep*. 10:448–462.
- Okafor I, Nnamah U, Ahiatrogah S, Serwaa D, Nnaka J. (2021). Reproductive toxicity potentials of methanolic extract of *Portulaca oleracea* in male rats: An experimental study. *Int J Reprod Biomed*. 19(3):245–254.
- Organization of Economic Cooperation and Development (OECD). (2022). Test No. 425: Acute Oral Toxicity: Up-and-Down Procedure. Organisation for Economic Co-operation and Development. https://www.oecd-ilibrary.org/environment/test-no-425-acute-oral-toxicity-up-and-down-procedure_9789264071049-en
- Orieke D, Ohaeri OC, Irene Ijeh I, Ijioma SN. (2019). Semen quality, hormone profile and histological changes in male albino rats treated with *Corchorus olitorius* leaf extract. *Avicenna J phytomed*. 9(6):551–562
- Ovie FO, Oliver NL, Nwanama EK, Elem CJ, Onyewuchi MO, Esomachi CN. (2023). Reproductive record on Ethanolic Extract of *Moringa Oleifera* Seed on the Testes of Adult Wistar Rats. *Eur J Theor Appl Sci*. 1(5):796–804.
- Perreault SD, Cancel AM. (2001). Significance of incorporating measures of sperm production and function into rat toxicology studies. *Reproduction*. 121(2):207-216.
- Rietjens IMCM, Lousse J, Beekmann K. (2017). The potential health effects of dietary phytoestrogens. *Br J Pharmacol*. 174(11):1263–1280.
- Ritchie C, Ko EY. (2021). Oxidative stress in the pathophysiology of male infertility. *Andrologia*. 53(1): e13581.
- Salhi S, Rahim A, Chentouf M, Harrak H, Bister JL, Hamidallah N, et al. (2024). Reproductive Enhancement through Phytochemical Characteristics and Biological Activities of Date Palm Pollen: A Comprehensive Review on Potential Mechanism Pathways. *Metabolites*. 14(3):166.

- Sengupta P, Pinggera GM, Calogero AE, Agarwal A. (2024). Oxidative stress affects sperm health and fertility-Time to apply facts learned at the bench to help the patient: Lessons for busy clinicians. *Reprod Med Biol.* 23(1): e12598.
- Skoracka K, Eder P, Łykowska-Szuber L, Dobrowolska A, Krela-Kaźmierczak I. (2020). Diet and Nutritional Factors in Male (In)fertility-Underestimated Factors. *J Clin Med.* 9(5):1400.
- Uchewa O, Egwu A, Uzomba C, Uchewa E, Egwu O. (2020). *Ficus vogelii* Stembarks; A Promising Herbal Remedy for Lead Induced Reproductive Toxicity. *BioMedica* 36(2):138–45.
- Uchewa OO, Chukwuemelie CE, Ovioson AI, Ibegbu AO. (2023). Alleviating Effects of Clove Essential Oil Dissolved in Dimethyl Sulfoxide (DmsO) Against Cadmium-Induced Testicular and Epididymal Damages in Male Wistar Rats. *Arch Razi Inst.* 78(6):1728–1737.
- Wanibuchi H, Kang JS, Salim EI, Morimura K, Fukushima S. (2003). Toxicity vs. beneficial effects of phytoestrogens. *Pure Appl Chem.* 75(11–12):2047–2053.
- World Health Organisation. (1999). WHO Laboratory Manual for the Examination of Human Semen and Sperm-Cervical Mucus Interaction. United Kingdom: Cambridge University Press; p.218-223
- Yokoi K, Mayi ZK. (2004). Organ apoptosis with cytotoxic drugs. *Toxicology.* 290:78-85.